



Uses of Fundus Autofluorescence

Dr Urmi P Shah
Dr Vatsal S Parikh



Introduction

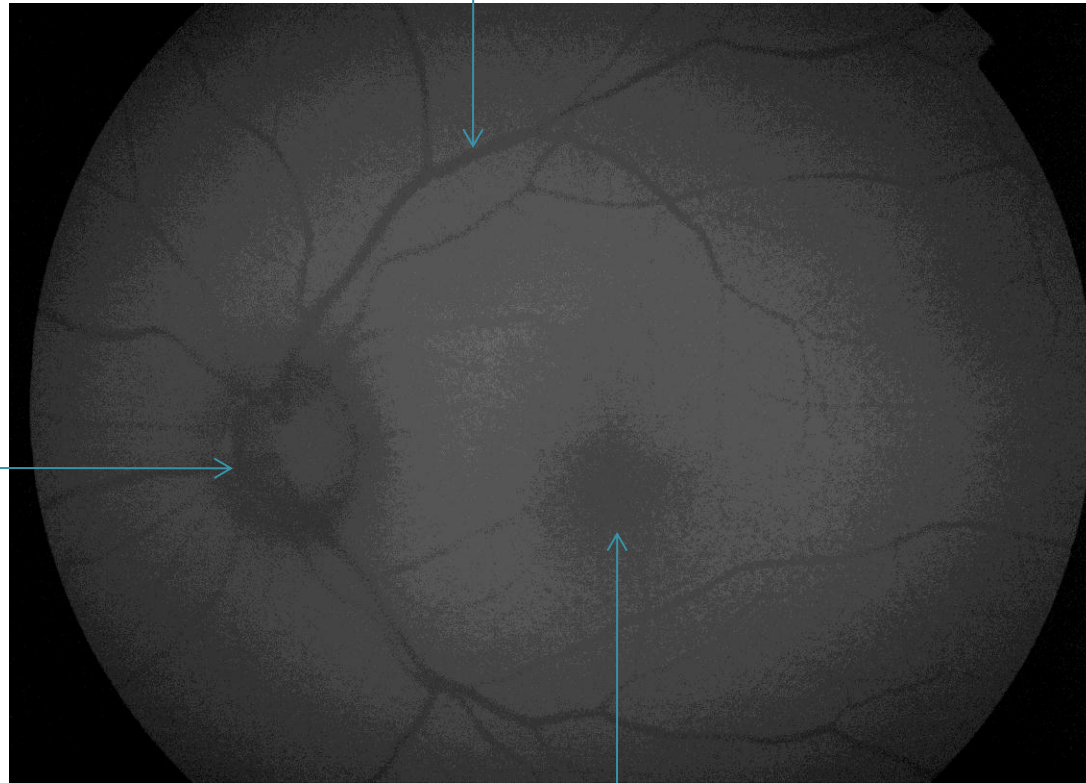- Fundus Autofluorescence (FAF) is an imaging technique for the health of retinal pigment epithelium (RPE)
- Lipofuscin (LF) accumulation in RPE cells results in hyperautofluorescence
- LF is by product of photoreceptor metabolism. Normally gets cleared - Excessive accumulation of LF occurs in ARMD, retinal disease and various retinal dystrophies such as Bests, Stargardts, RP.
- Atrophy or destruction of RPE causes hypoautofluorescence



Normal Fundus Autofluorescence

FAF blocked by blood column

Absence of LF



Absorption by macular pigments – lutein and zeaxanthin

- FAF is a very simple, fast and non invasive technique, to provide additional information about retinal disease

FAF has been very useful

- To confirm the diagnosis
- To monitor patient and decide further treatment
- To follow up and see disease progression over years

Images captured by Topcon fundus camera





FAF IN CHOROIDITIS



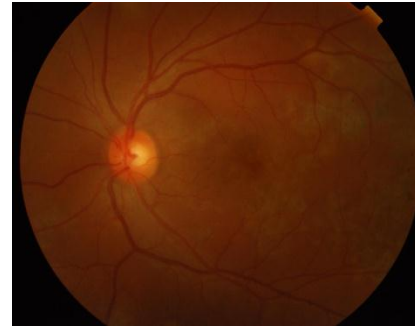
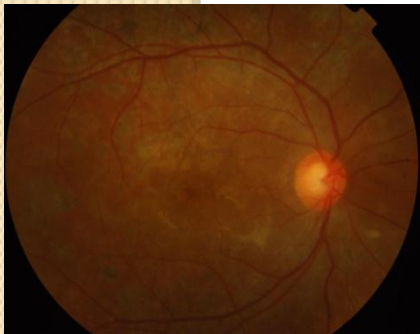
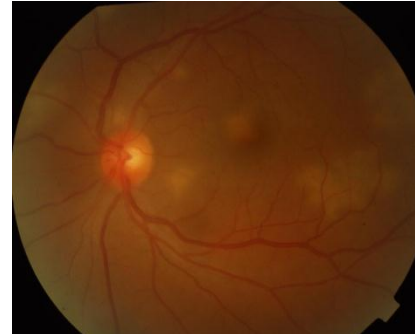
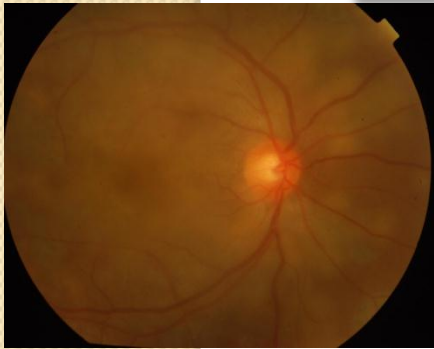Serpiginous Choroiditis

Ref no 11-02302

11-11-2011

6/18, N8

6/6, N6



6/6p, N6

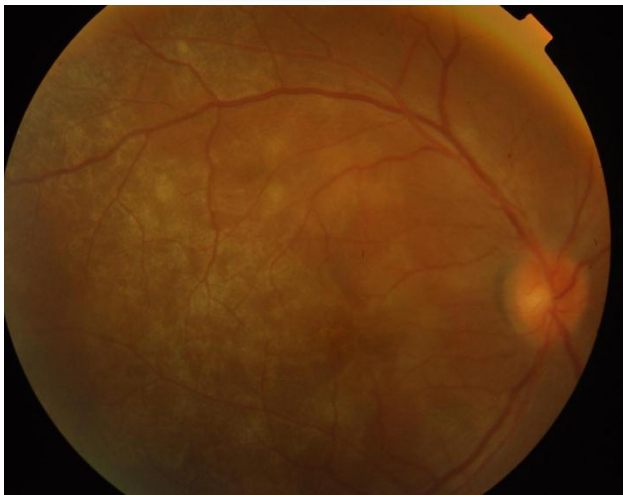
15-2-2012

6/6, N6

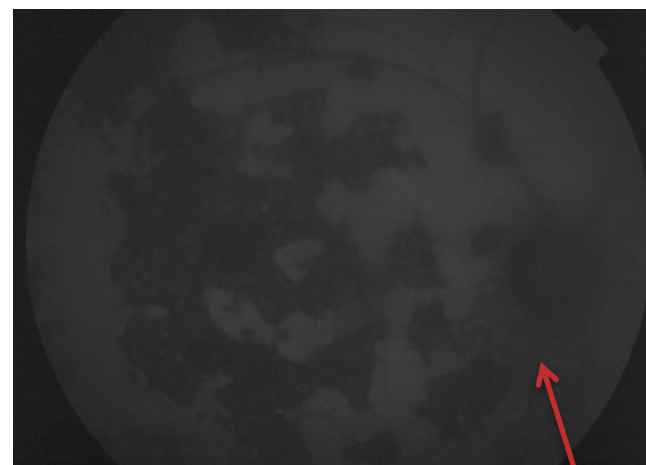
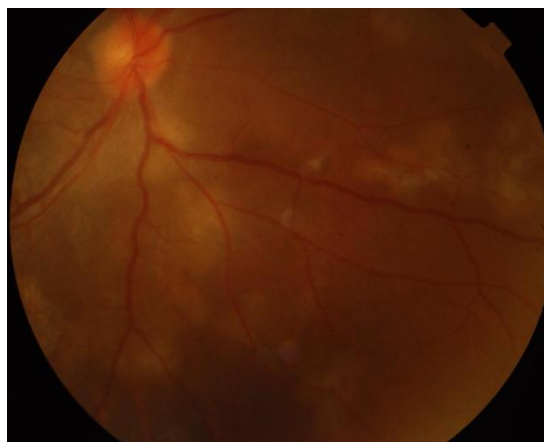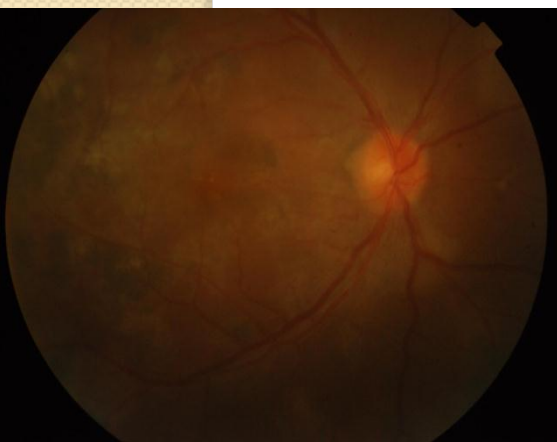



Ref No 12-01540

CF 1 1/2 mt




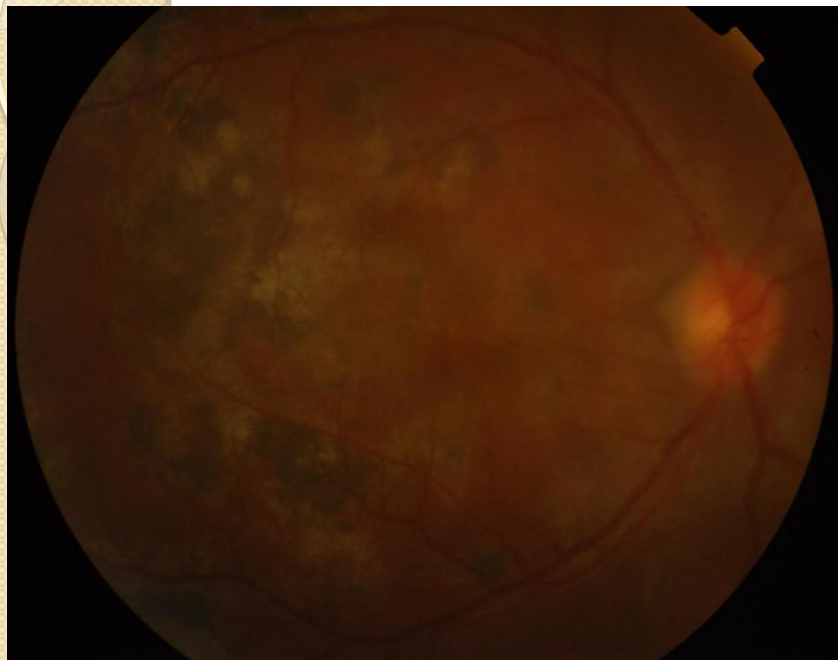
26-7-2012



6/6, N6


17-12-2012





7-1-2013





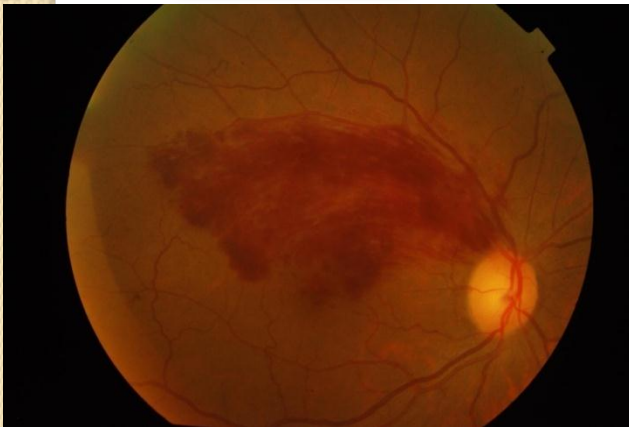
EFFECT OF LASER PHOTOCOAGULATION ON RPE



Ref No 11-01383

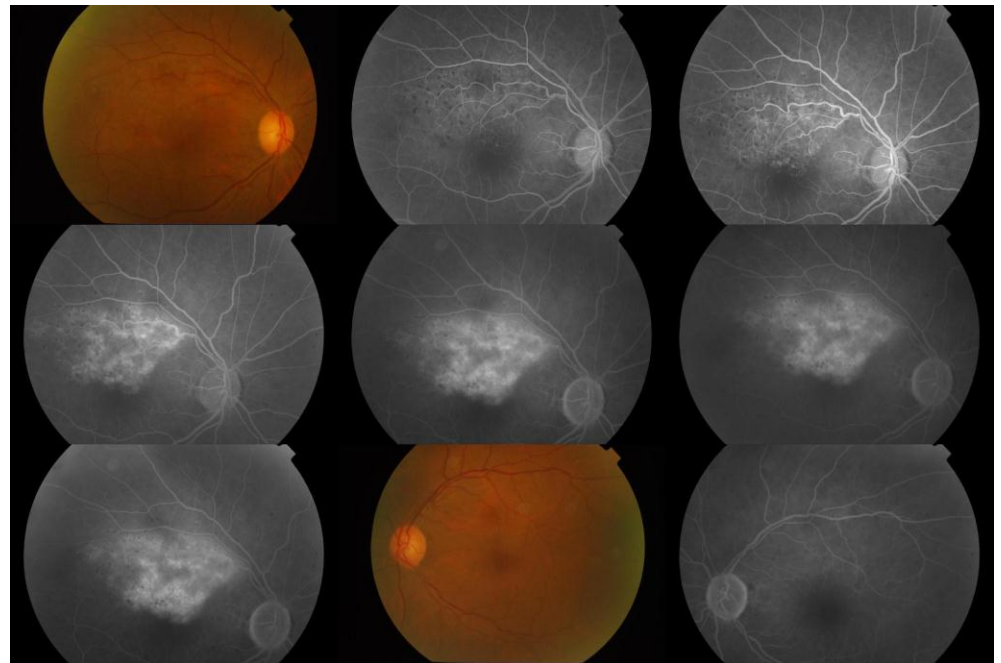
55 / F with superotemporal BRVO

6/24, N36



26-7-2011

oct



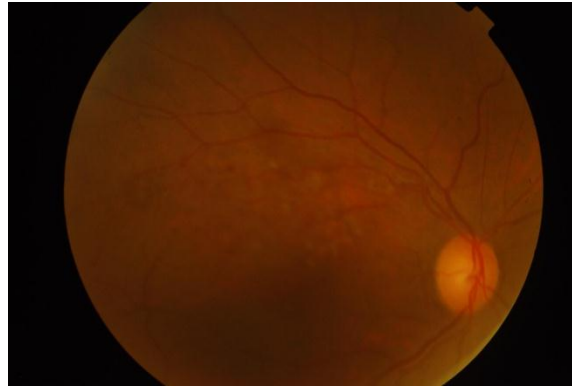
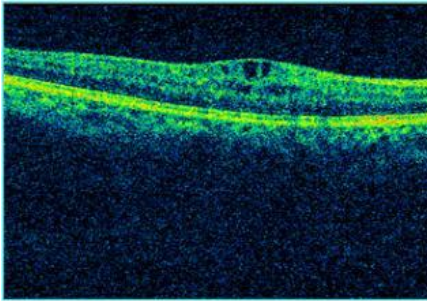
10-12-2011

- 4 Anti vegf injections
- Laser on 1/11/11
- Ozurdex on 13/3/12



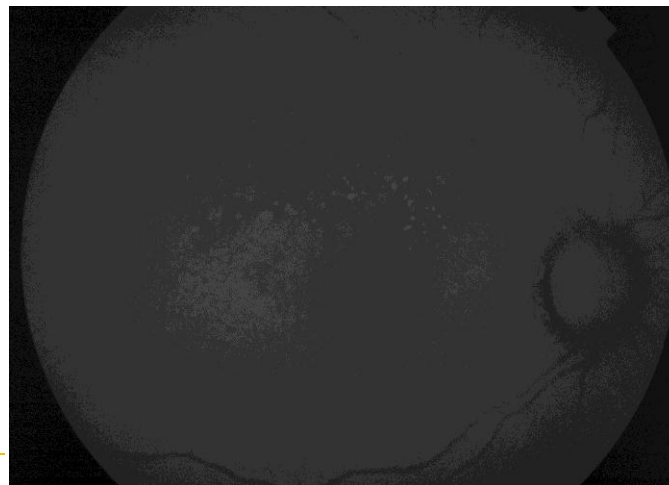
28-3-2012

6/6p, N10

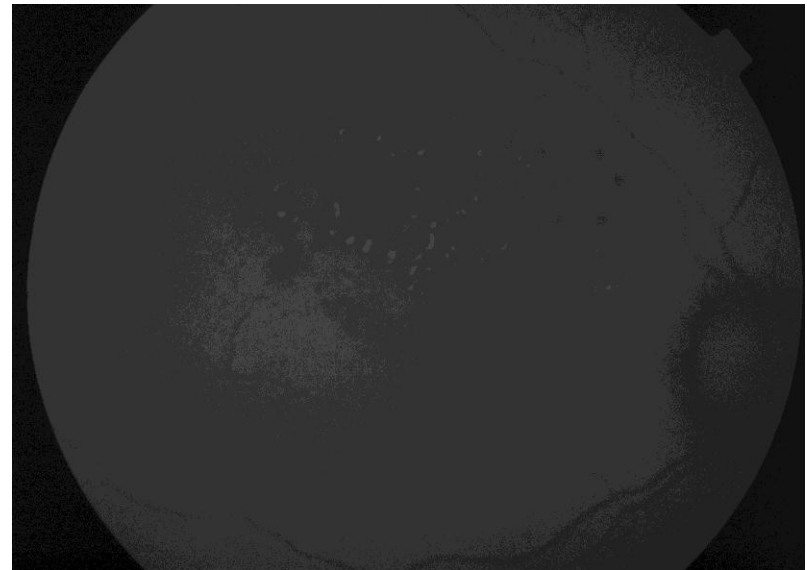
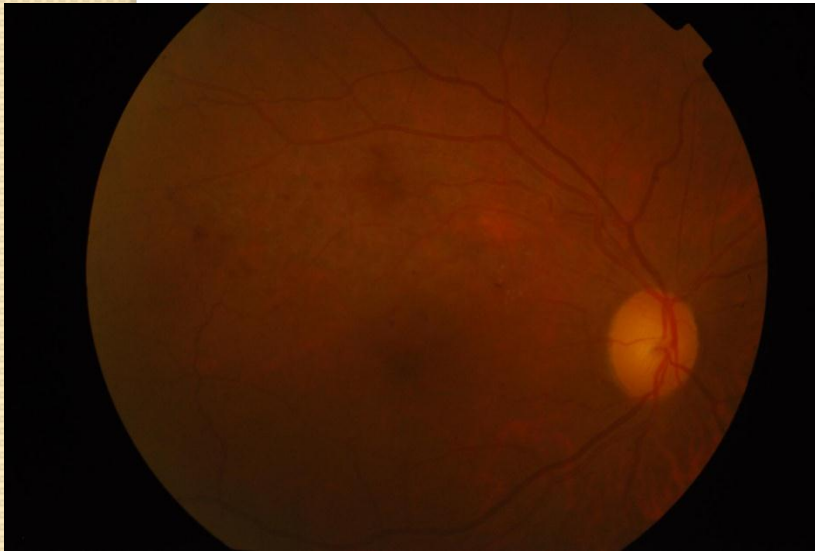

Decided to laser closer to FAZ on 28-3-12

11-4-2012



Further received focal laser on 5-11-12



21-11-12

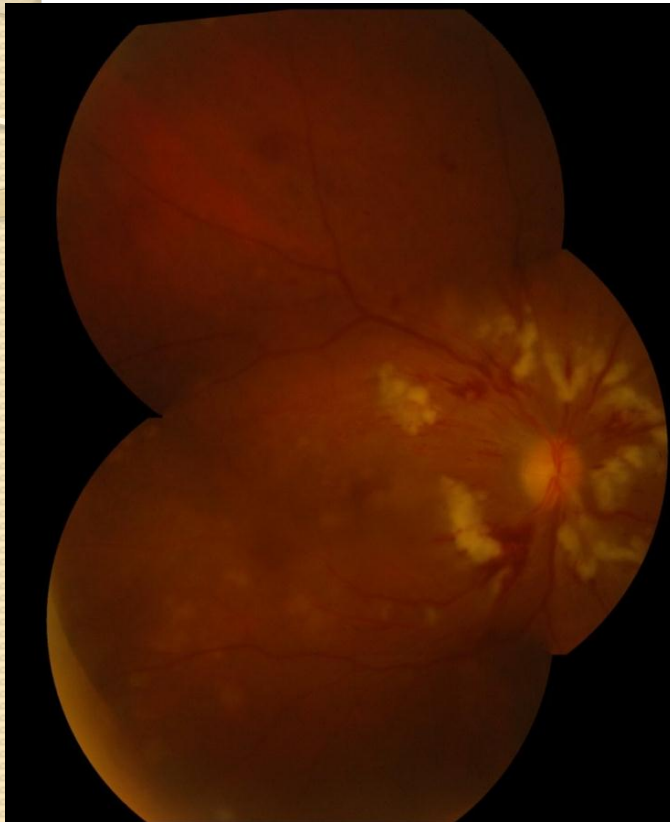



FAF HELPS TO CONFIRM THE DIAGNOSIS

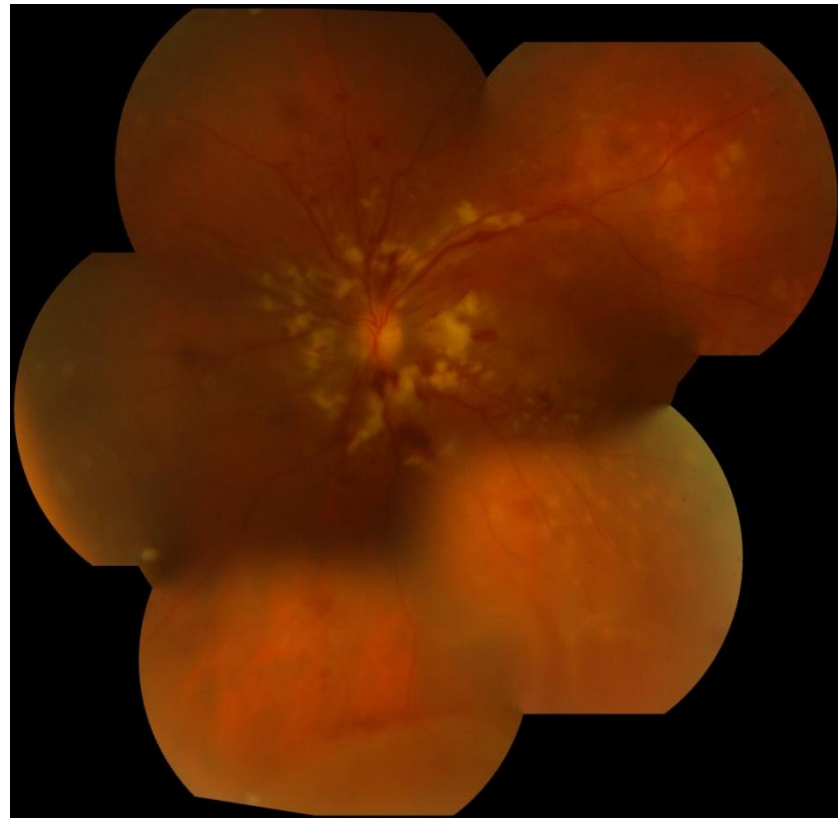


6/18, N36



? / M drop in vision X 10 days L > R ,
Not known diabetic or hypertensive

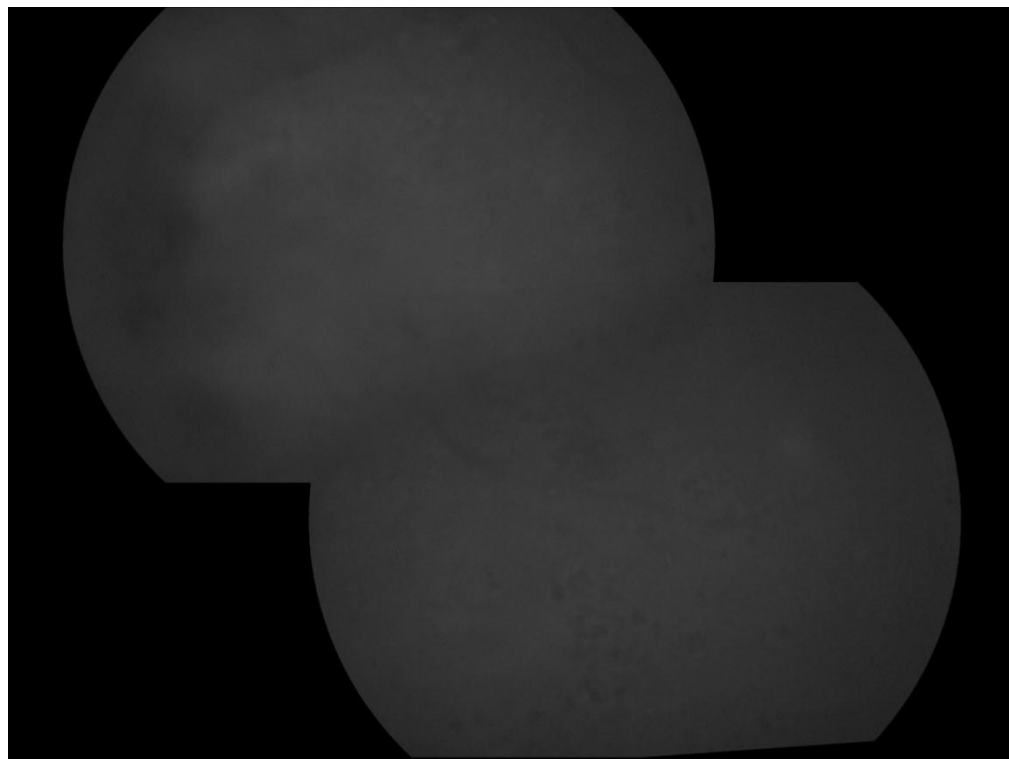

CF I mt



DD of retinal hemorrhages –

- Diabetic retinopathy,
- hypertensive retinopathy
- B/L CRVO
- Vasculitis





ELSCHNIG SPOTS

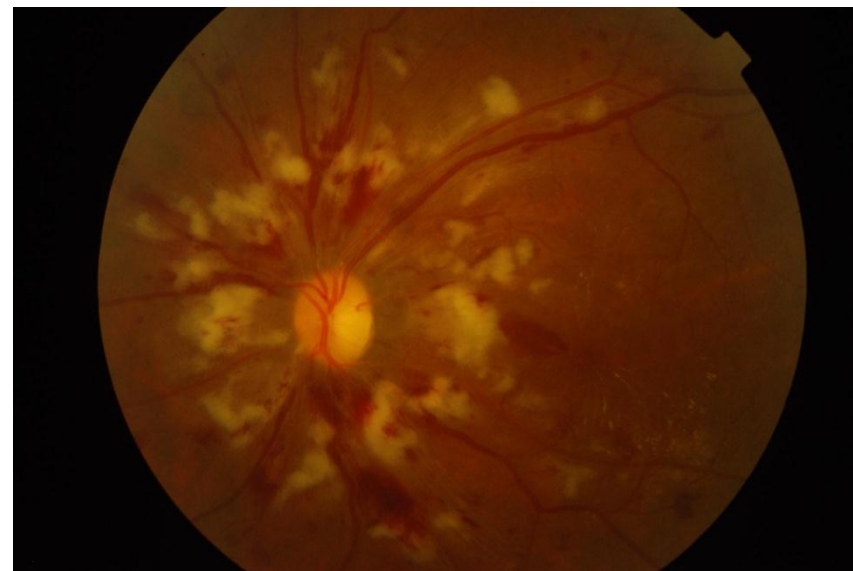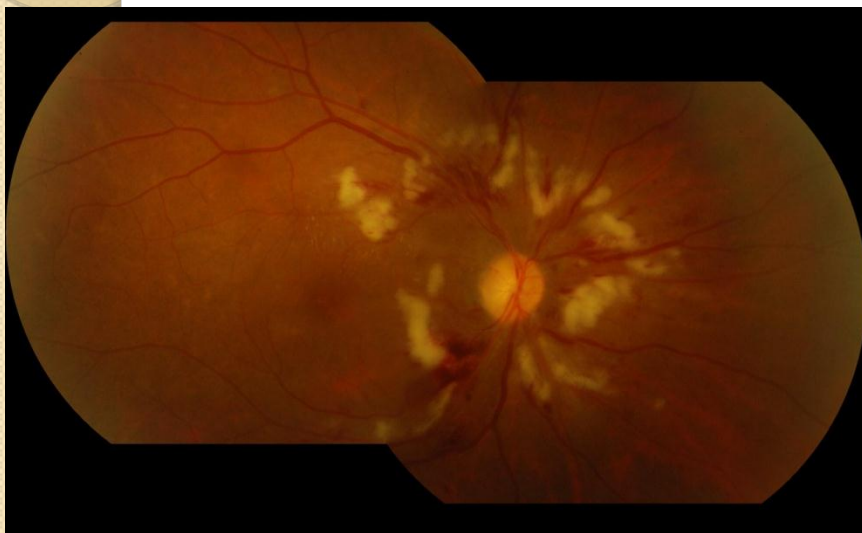
BP – 200/130 !!!



1/3/2013

6/18, N8

CF 3 mts

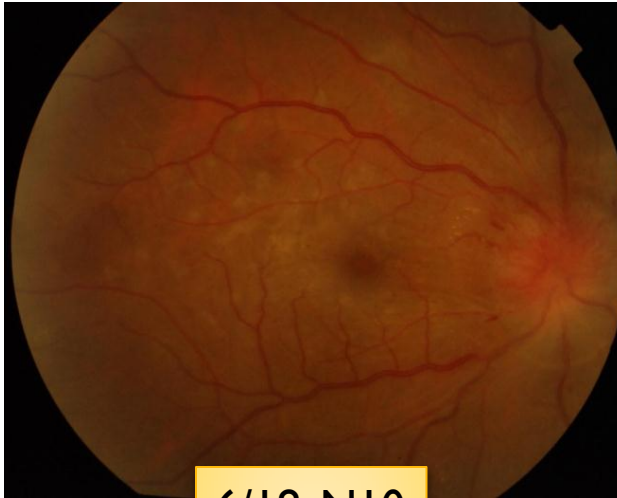

BP 120 / 70

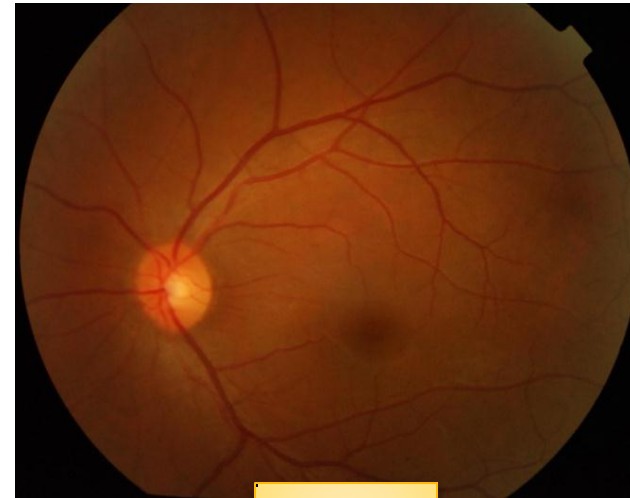

Ref No 14-01427

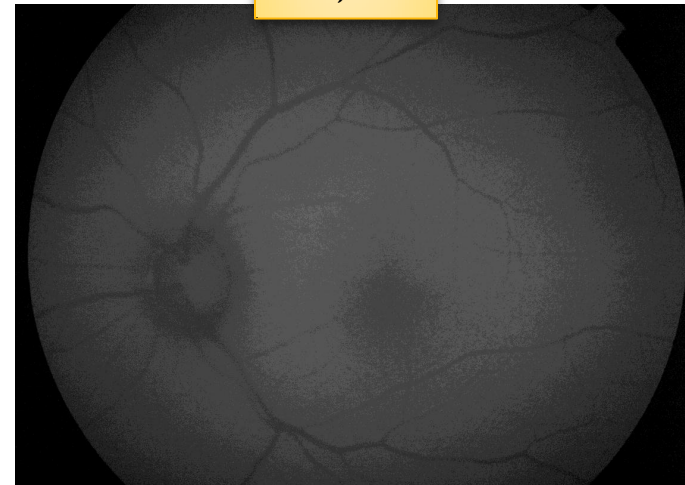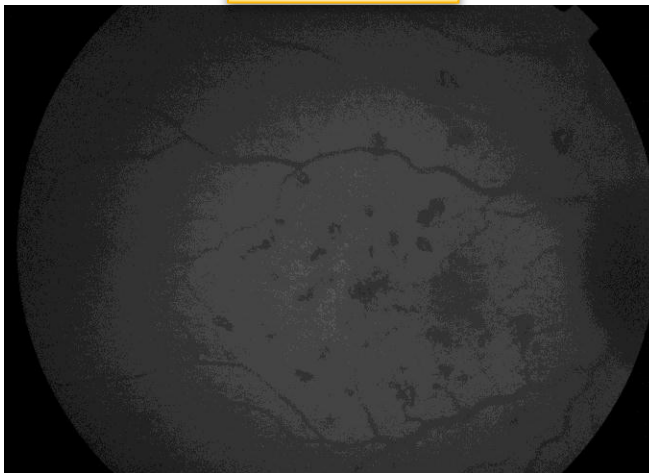
Blurred vision right eye since 4 months

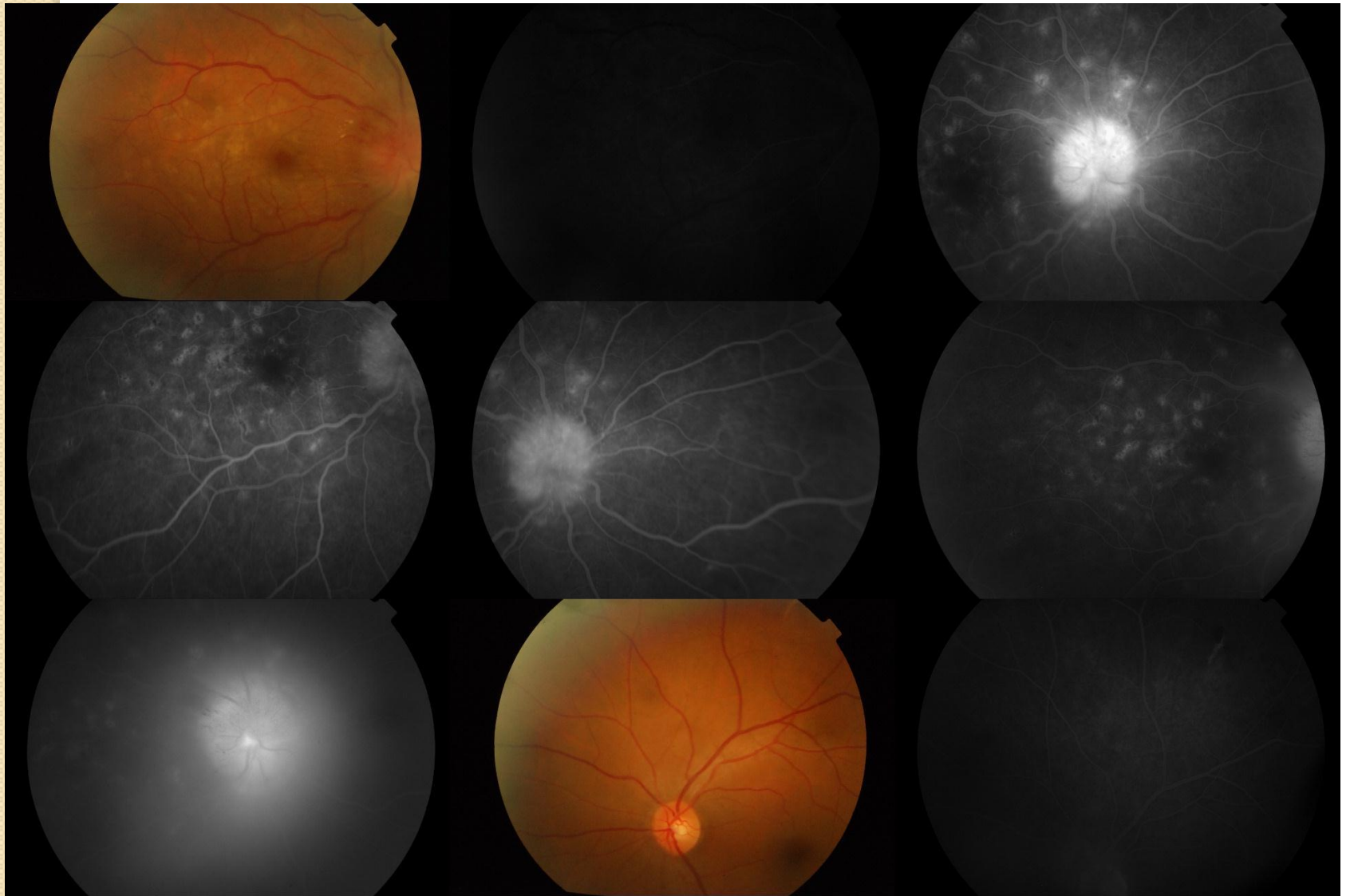


6/18, N10



6/6, N6







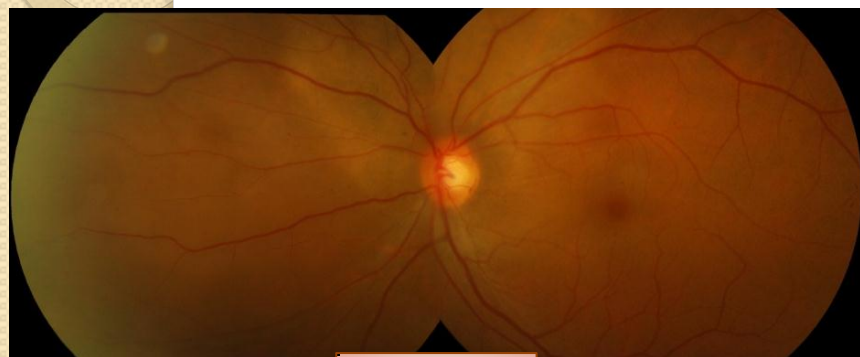
FAF IN CHOROIDAL METASTASIS



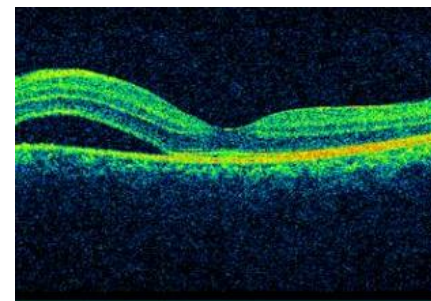
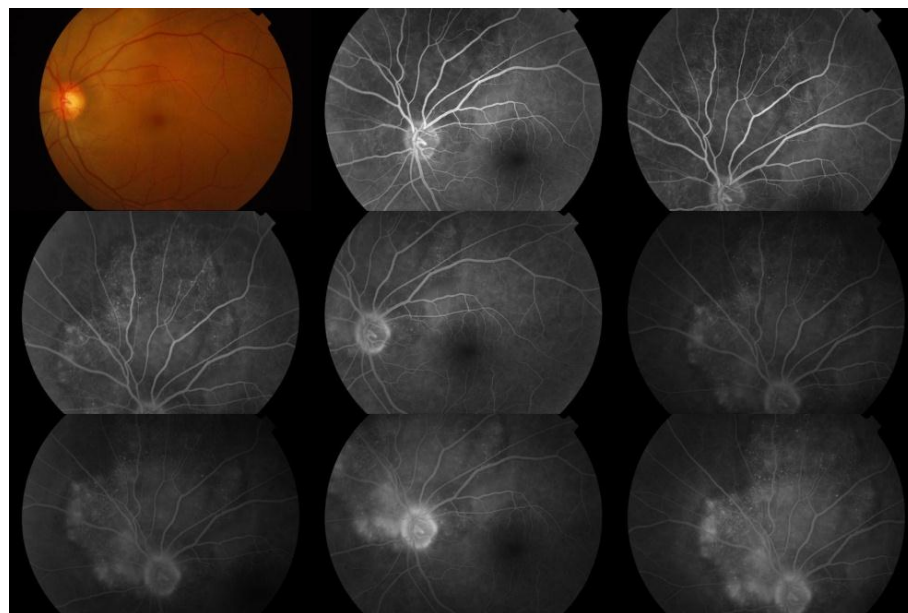
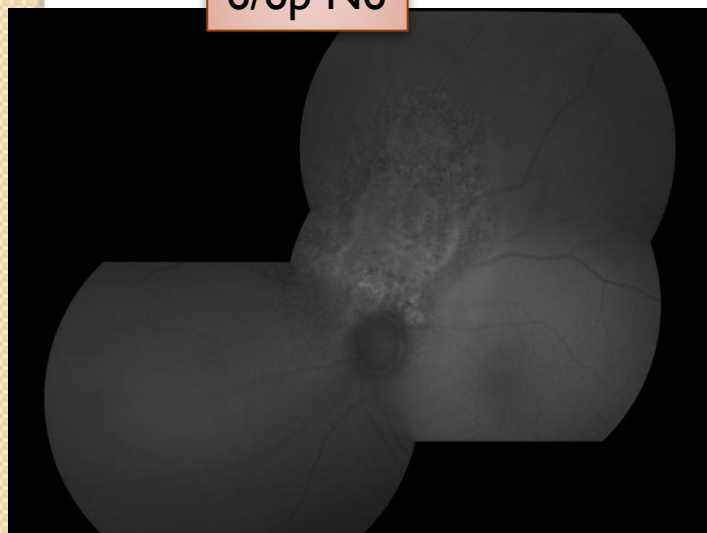
29-12-2011

Ref No 11-02710

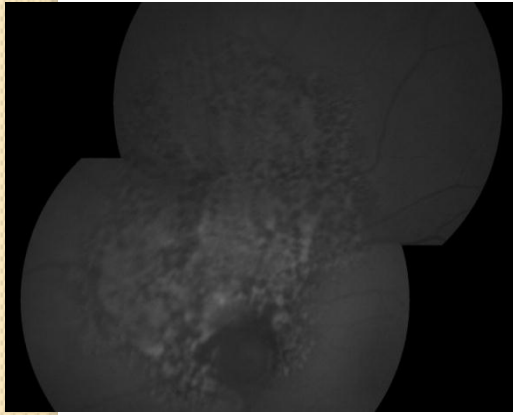
- ? / F, h/o breast ca on treatment
- Blurred vision right eye temporally X 10 days



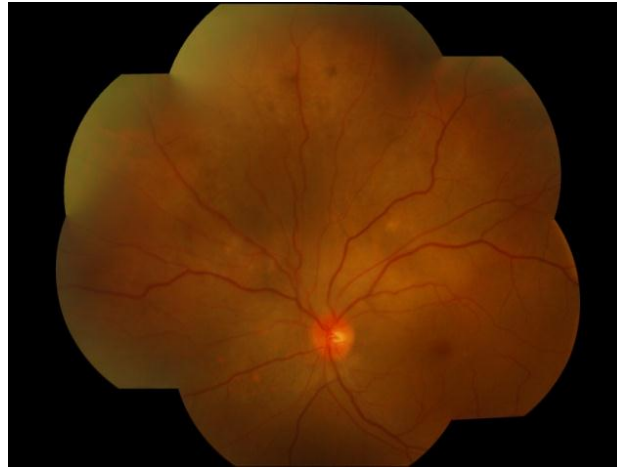6/6p N6



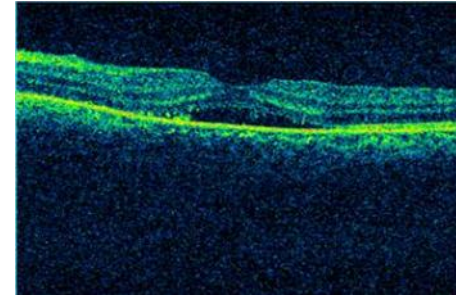
1-3-2012



6-6-2012

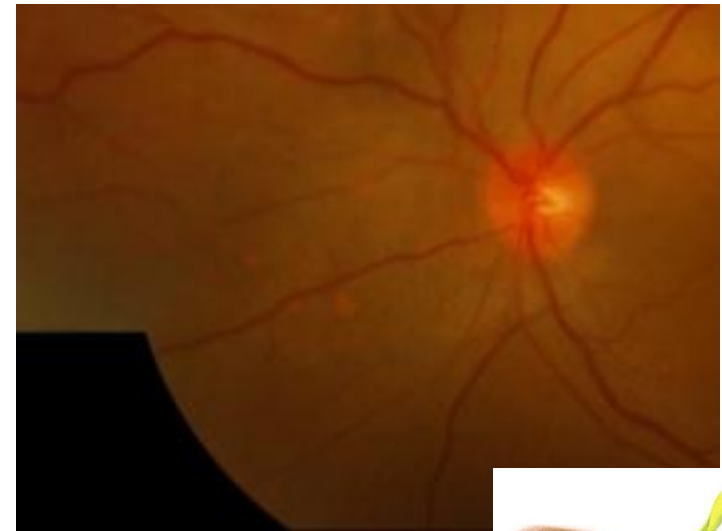
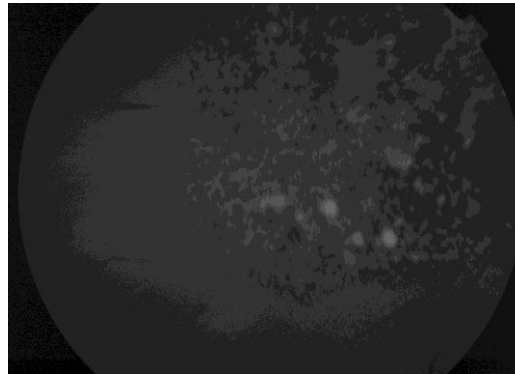
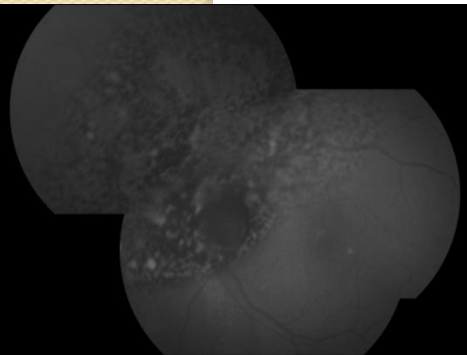


6/12, < N36




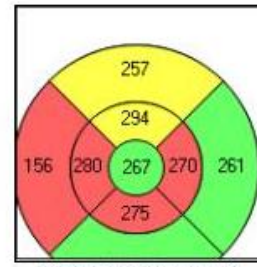
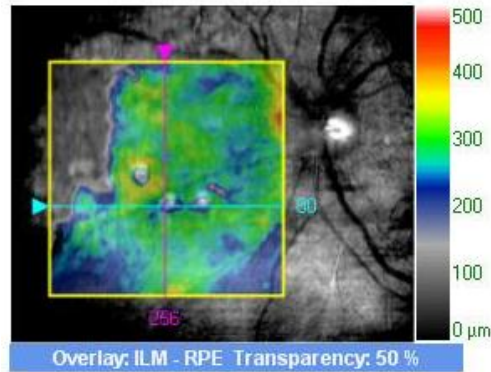
Drop in vision since 10days

6-6-2012

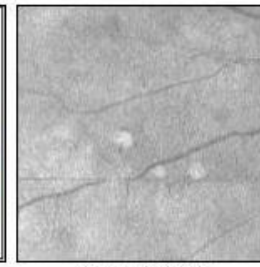


- Why vision drop – OCT
- Enlarge coloured photo to show mets


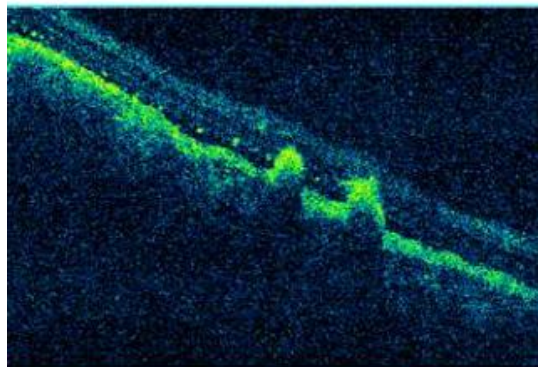




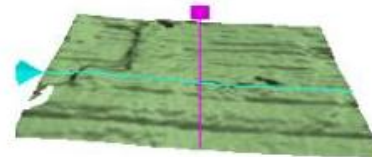
ILM-RPE Thickness (μm)



Fovea: 241, 82



ILM - RPE

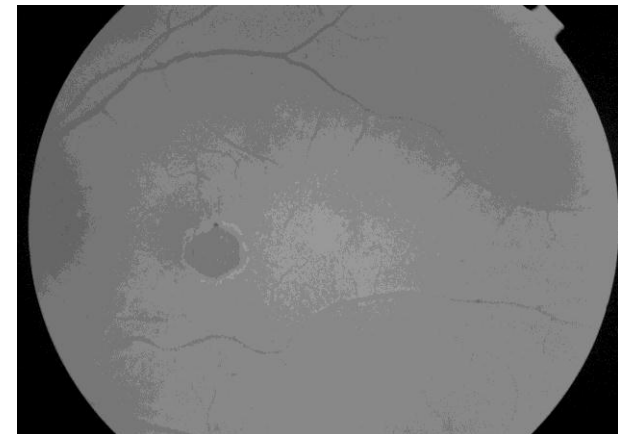
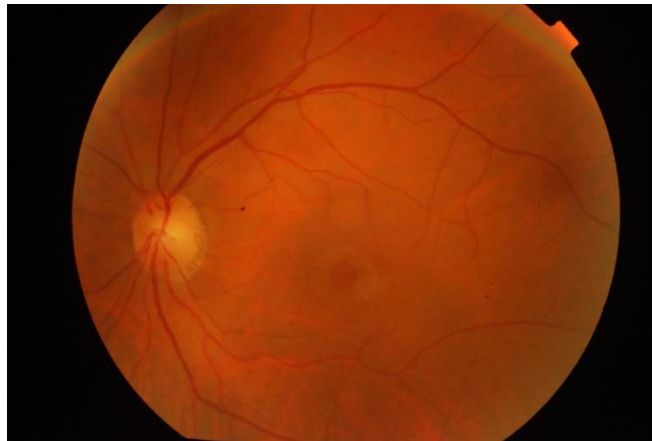
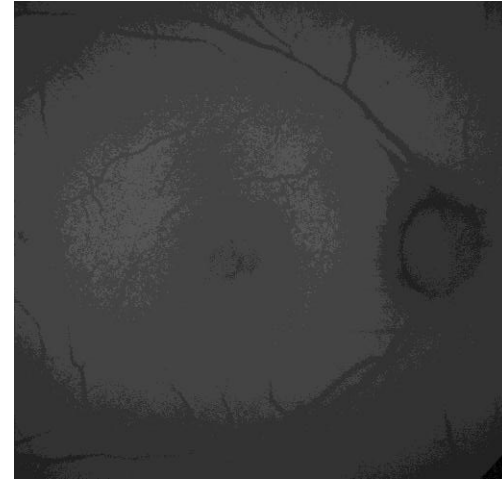
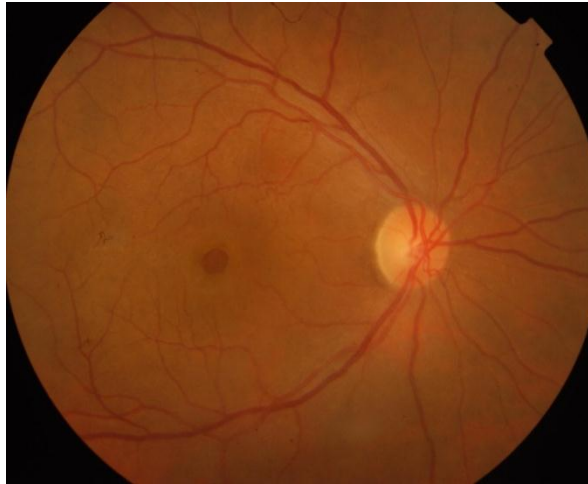


FAF in Macular Hole

Recent onset

Ref No 98-0346

VA : 6/36p, N36



Ref No 14-01043

VA : CF 1 mt

Long Standing





FAF IN ARMD



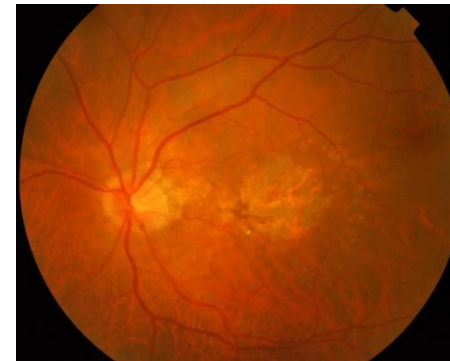

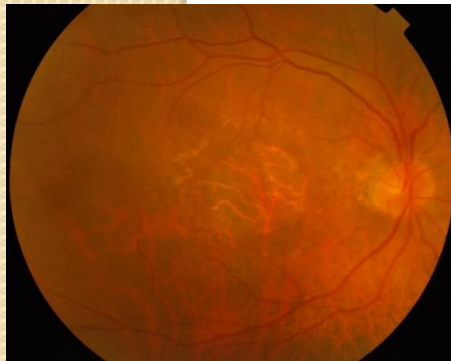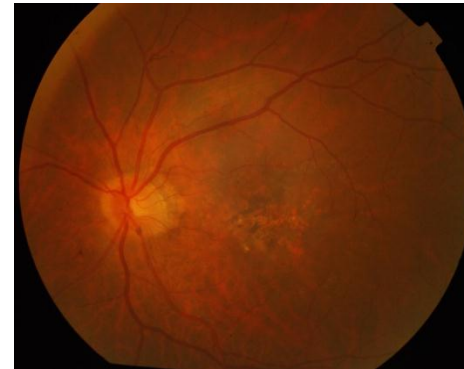
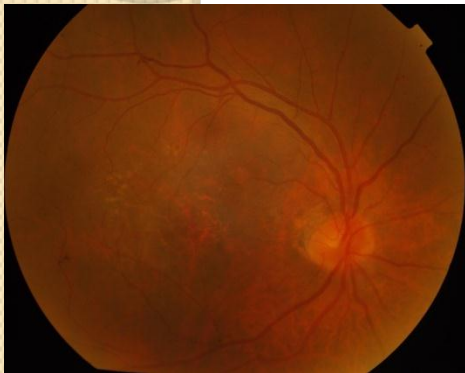

Geographic Atrophy

Ref No 11-01524

15-7-2011

6/60, N18p

6/6p, N6



6/60, N36p

13-8-2014

6/12, N10p



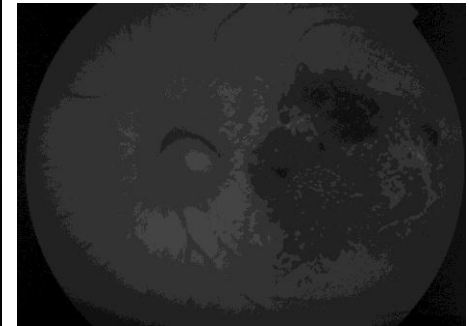
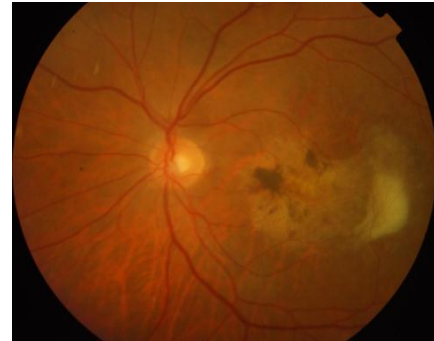
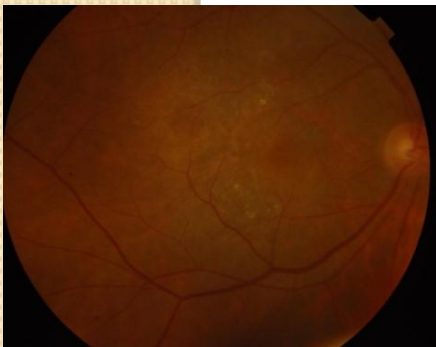
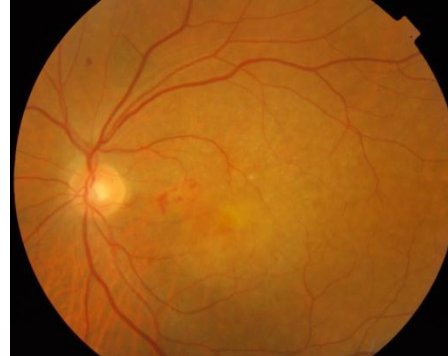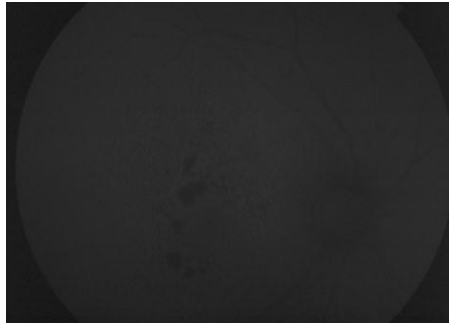
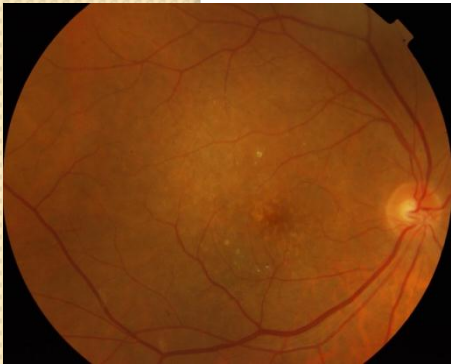Wet ARMD

Ref No 10-00148

25-10-2010

6/6, N6

6/18, N36



6/18 N18p

26-3-2013

CF 11/2 mt



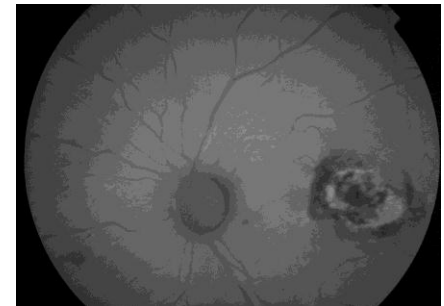
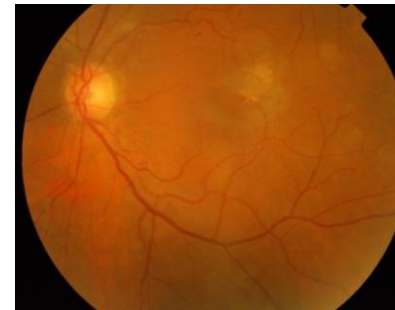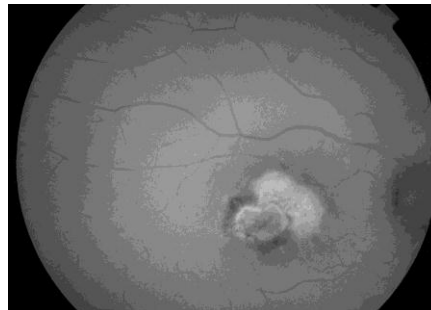
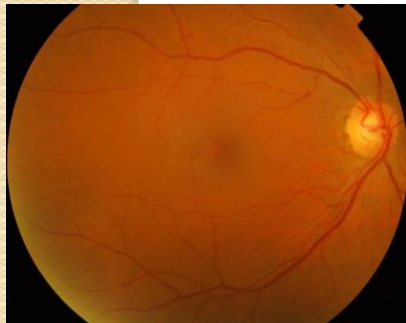
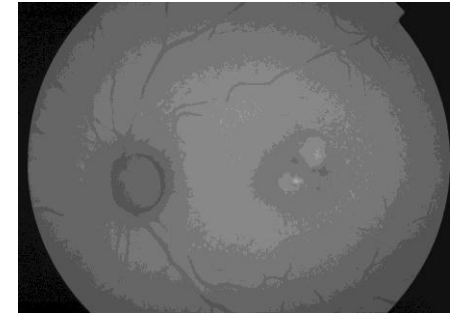
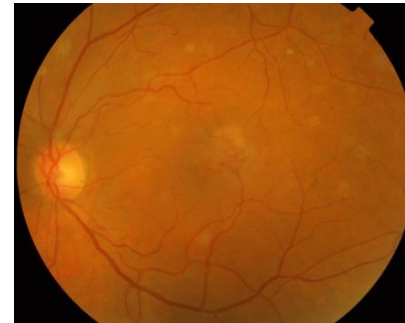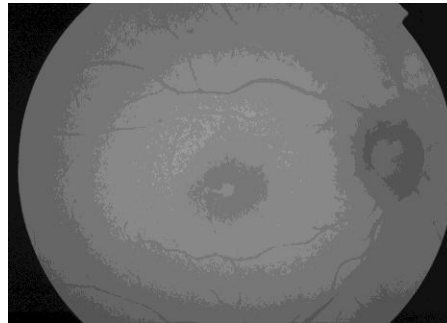
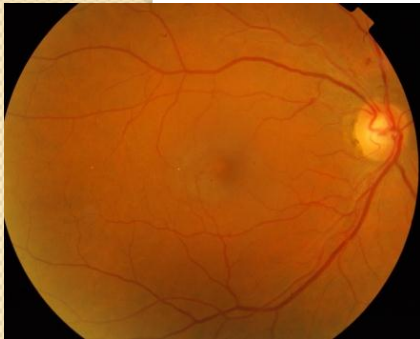Idiopathic Parafoveal Telangiectasia

Ref No 07-01159

6/9p, N8p

19-12-2007

6/12, N12



6/36, N18

31-7-2014

6/36, N10



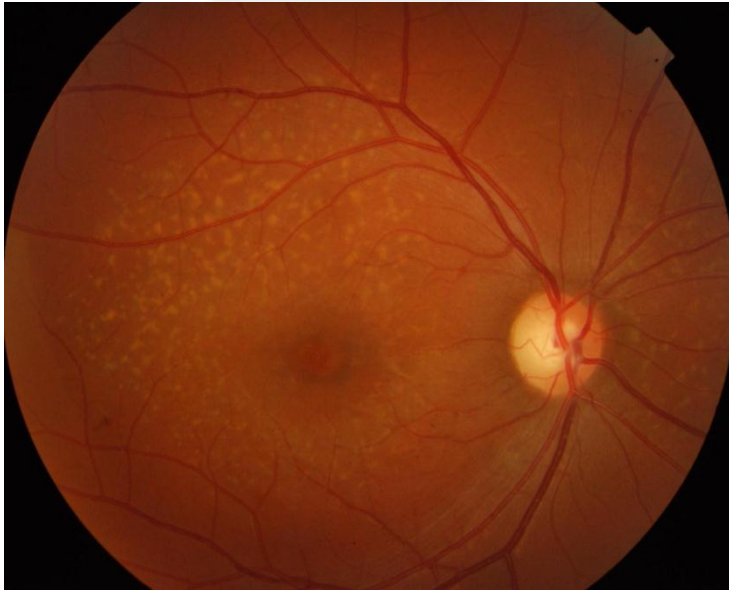

FAF IN RETINAL DYSTROPHIES

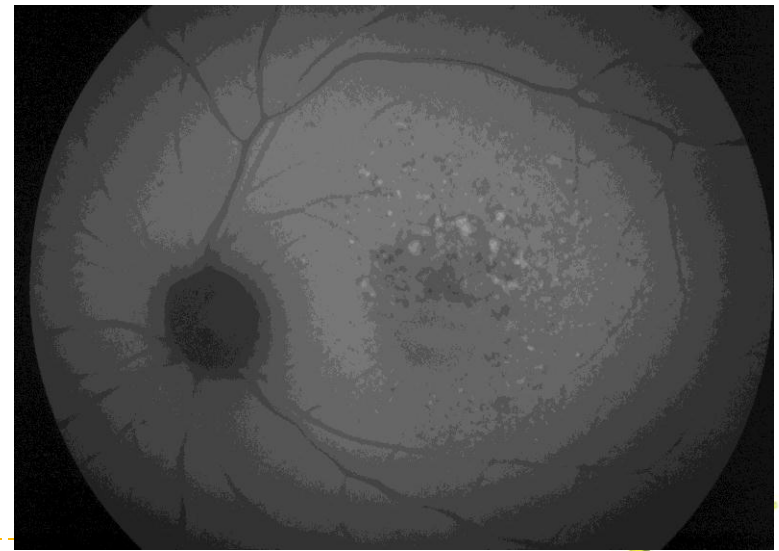
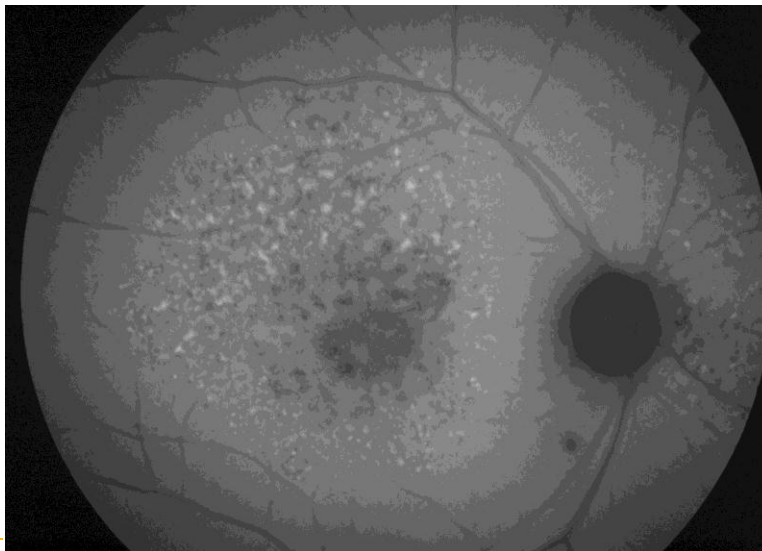
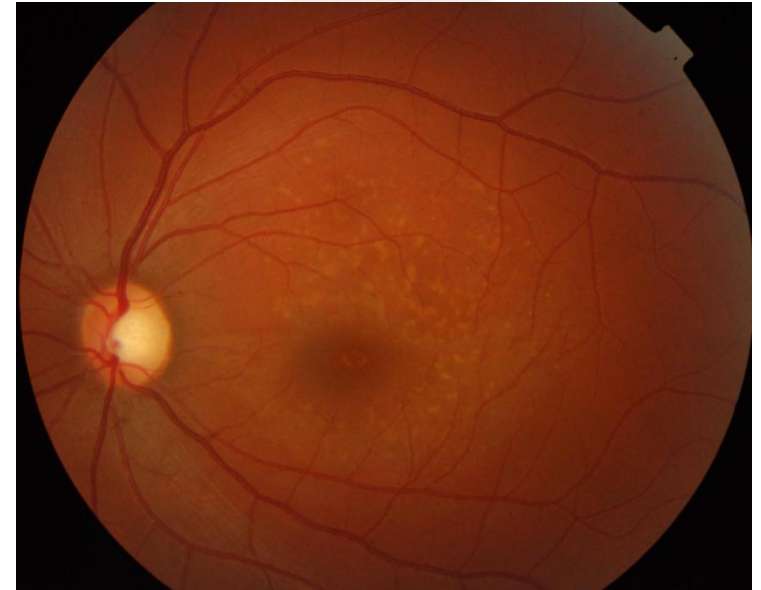


Ref No II-00946

6/60, < N36

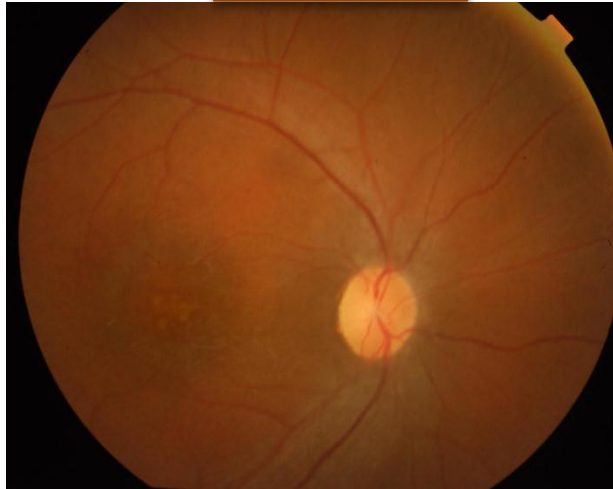

6/6p, N6


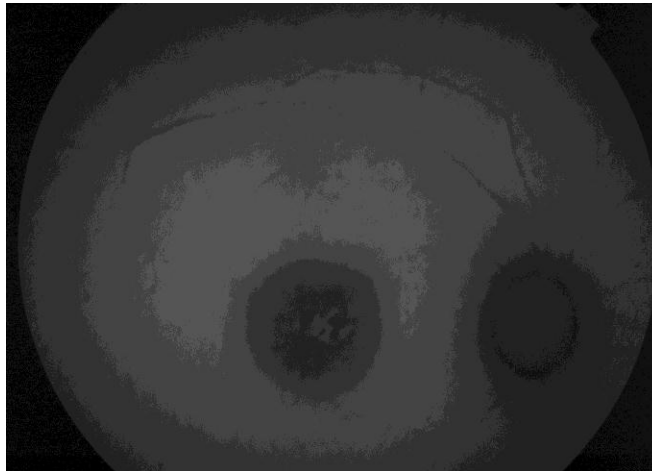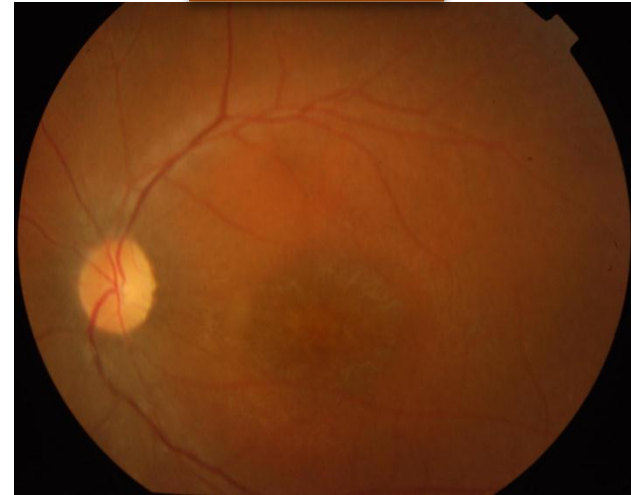


Ref No II-02522

6/60p, N36

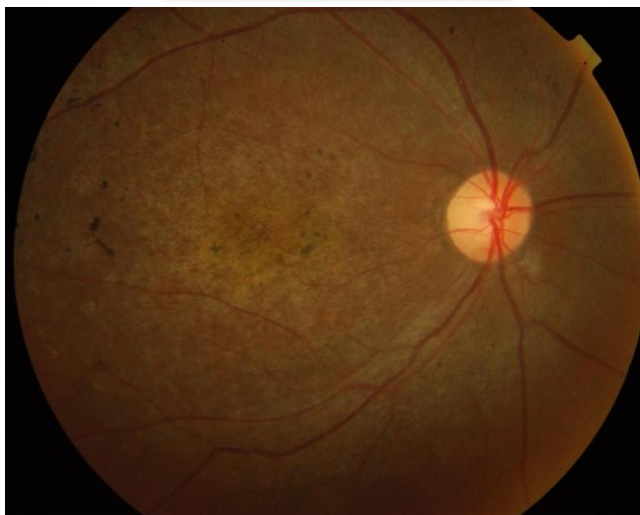

6/60p, N36

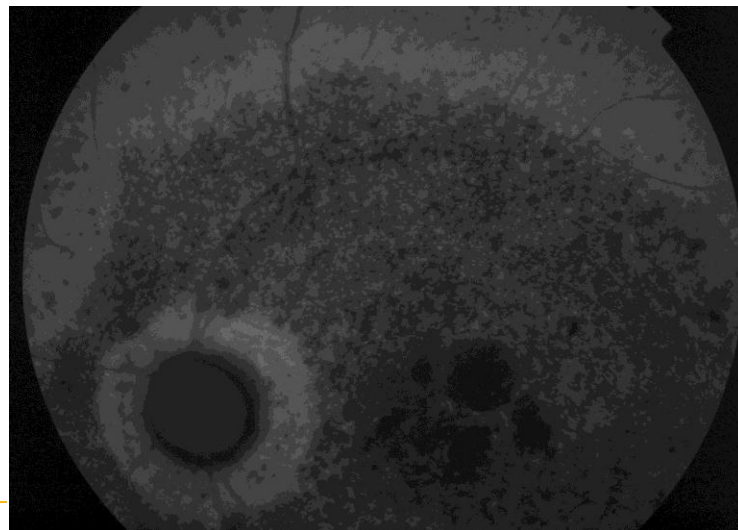
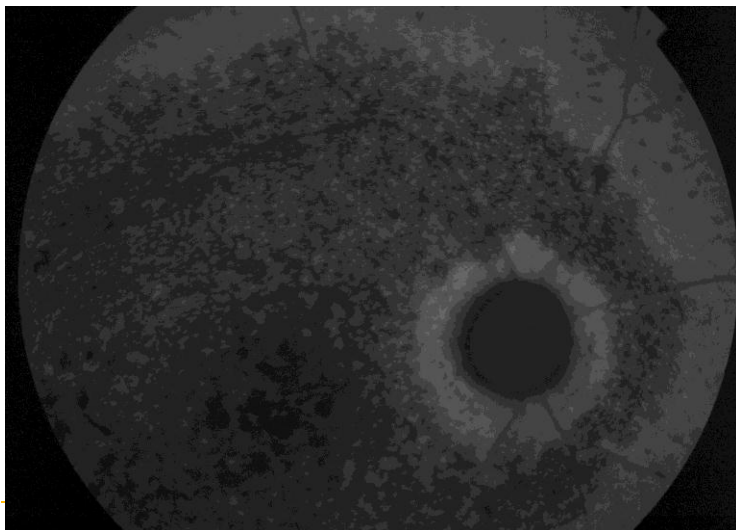
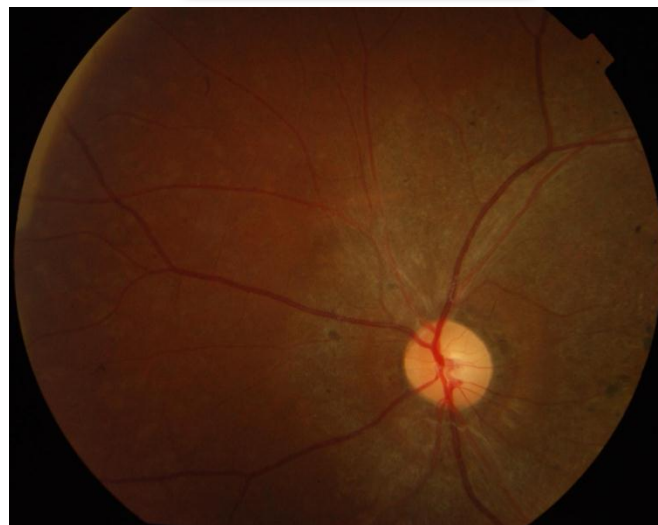

Ref No II-00497

CF 1 mt, < N36



CF 2 mt, < N36



CONCLUSION





Thank

You

