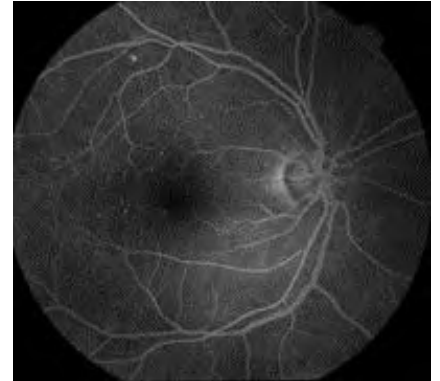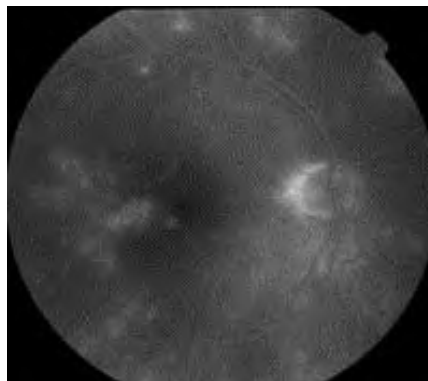

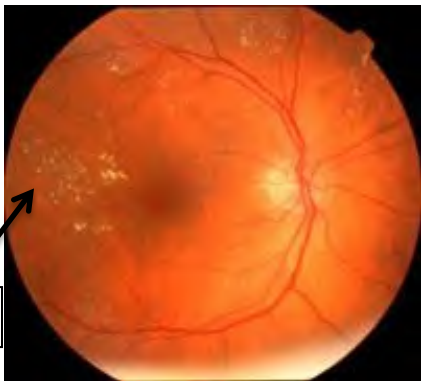
# Treatment of Diabetic Macular Edema without Intravitreal injections

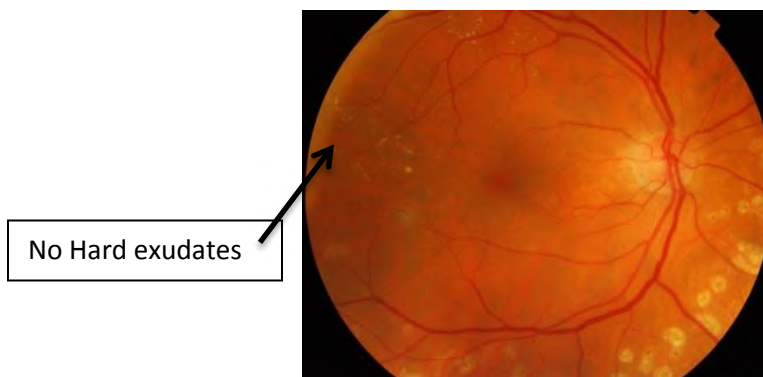
## 1. Treatment of macular edema with laser only

- This 60 year old female presented on 02-01-2007 for retinal evaluation.
- She had proliferative diabetic retinopathy with diabetic macular edema in both eyes. Vision was 6/6, N6.
- She was treated with macular grid laser followed by panretinal photocoagulation
- Right eye fundus picture shows that hard exudates reduced considerably within a year, following treatment with grid laser.

15-02-01-07, 6/6 N6



15-02-08 6/6 N6

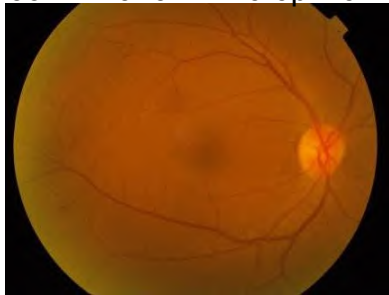


## 2. Natural course of untreated macular edema

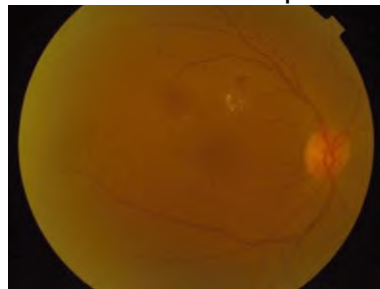
- This 63 year old female was a known diabetic on insulin since 12 years. In 2010
- Her right eye vision was 6/6, N6.
- However, her diabetes was uncontrolled, and she developed diabetic maculopathy – circinate ring above macula.
- She had irregular follow up, and edema was not treated and over course of time the exudates increased.
- These pictures show the natural course of untreated diabetic macular edema

**Ref No:- 08-01667**

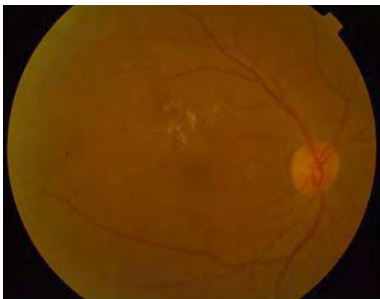09-11-2010 Vn:- 6/6p N6



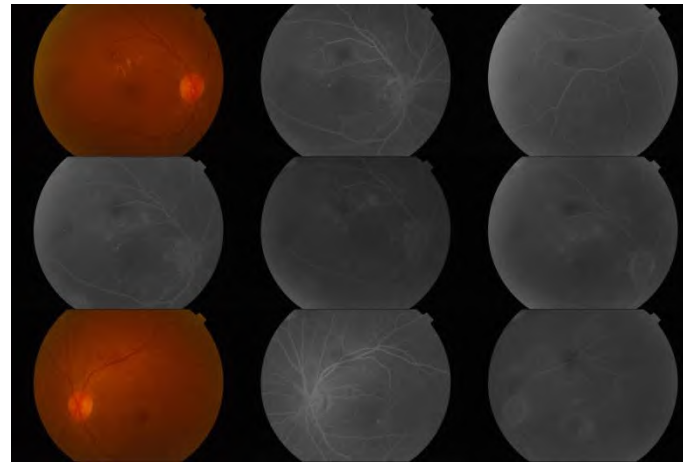
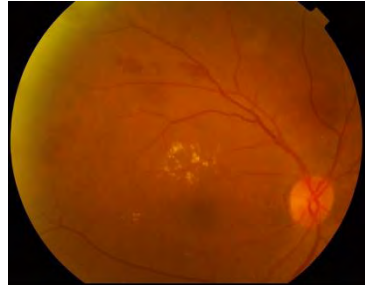
29-01-2013 Vn:- 6/6p N6



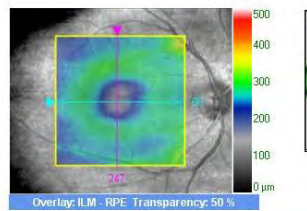
12-02-2014 Vn:- 6/6 N6



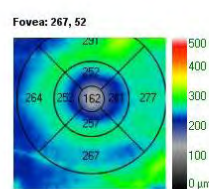
22-07-2014 Vn:- 6/36 N36




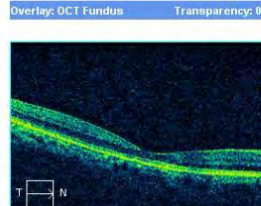
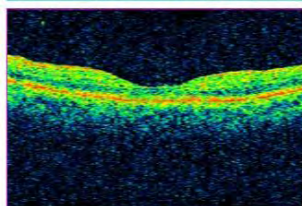
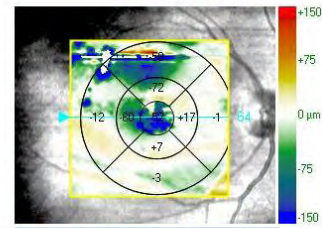
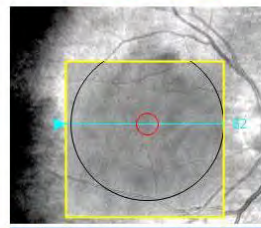
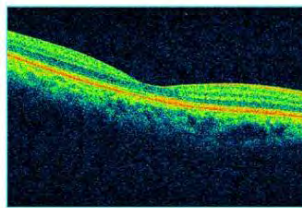
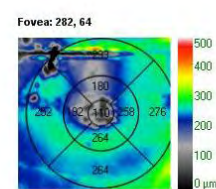
09-11-2010



29-01-2013



22-07-2014

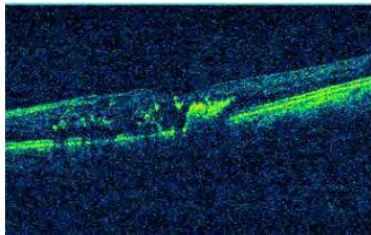
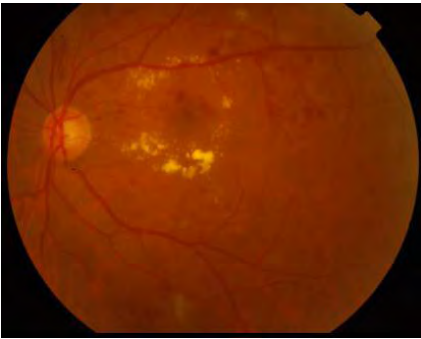

### 3. Improvement in macular edema with metabolic control only

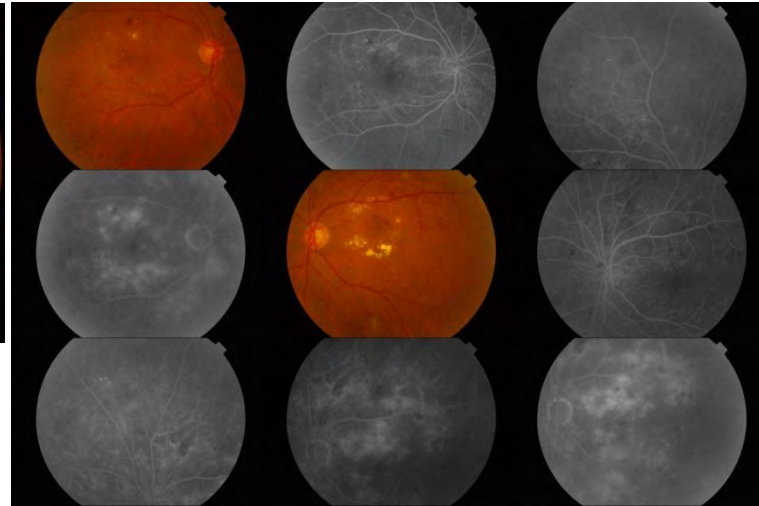
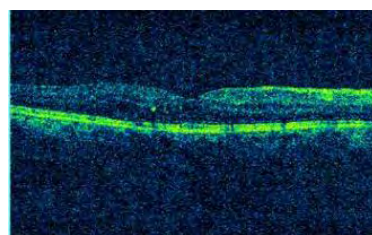
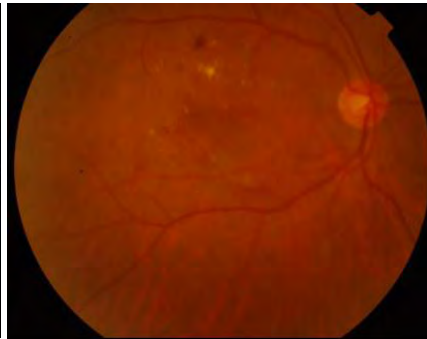
- This patient presented with both eyes diminishing vision was diabetic with poor metabolic control,
- fundus showing diabetic maculopathy. Both eyes vision 6/18 N10.
- Cholesterol-234, LDL-161, HbA1c-9.7.
- After controlling Metabolic disease he improved with 6/18 N10 in right eye & 6/6p N8 in left eye

**Ref No:- 14-00090**

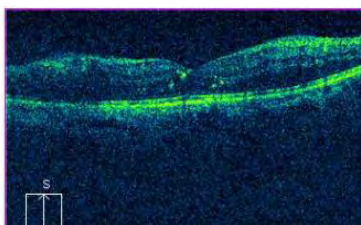
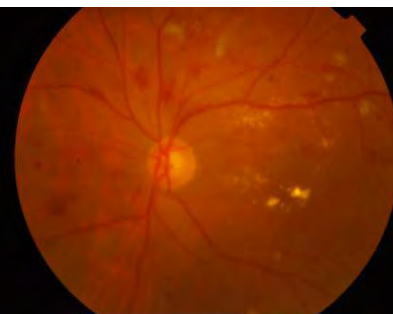**16-01-2014**



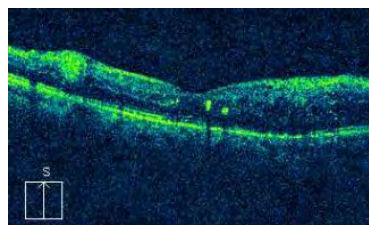
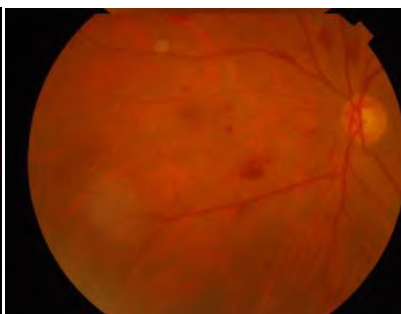
**16-01-2014**



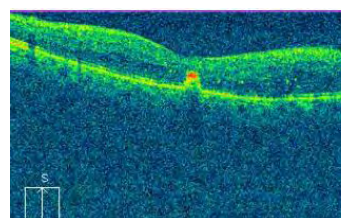
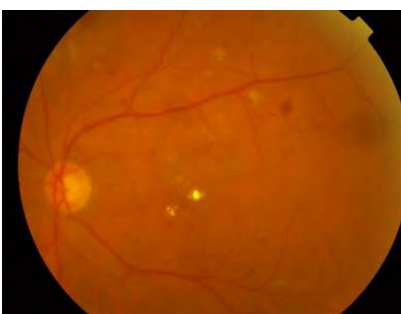
**24-03-2014 Vn:- 6/12 N10**



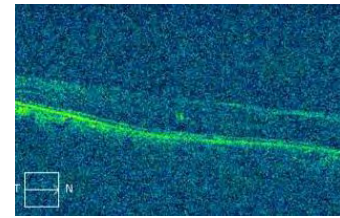
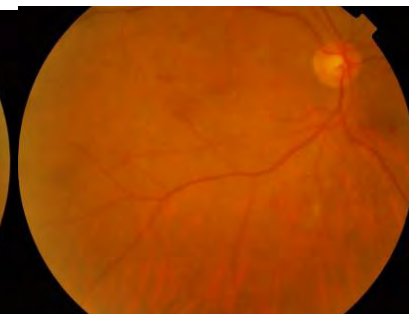**24-03-2014 Vn:- 6/12 N8**



**22-07-2014 Vn:- 6/24 N10**



**22-07-2014 Vn:- 6/6p N8**

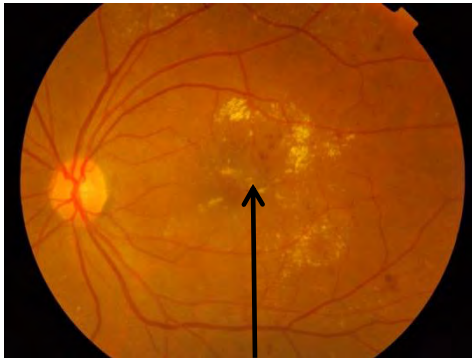

#### **4. Resolution of macular edema with laser and metabolic control**

- This 40 year old female patient presented with uncontrolled diabetes and lipids, and diabetic macular edema on 03-08-07.
- Her vision was 6/18, N10 in both eyes.
- She was advised strict control of sugar and lipids, and underwent laser in both eyes for the macular edema.
- Focal and grid laser were both done.
- Vision improved to 6/12, N10 in right eye and 6/6, N6 in left eye, and exudates completely cleared by 01-05-09.

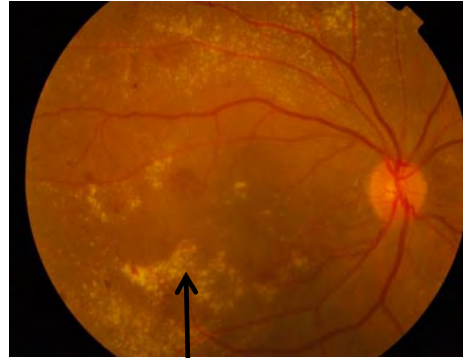
**Ref no. 07-01737**

03-08-2007 Vn:-6/18p N10



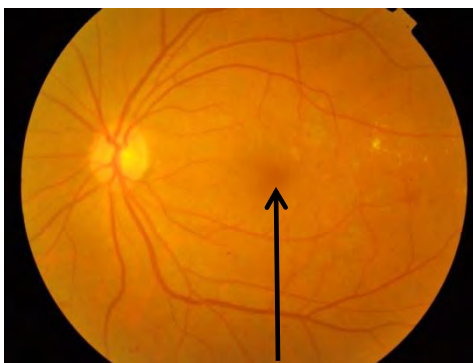Hard exudates

03-08-2007 Vn:-6/18p N10



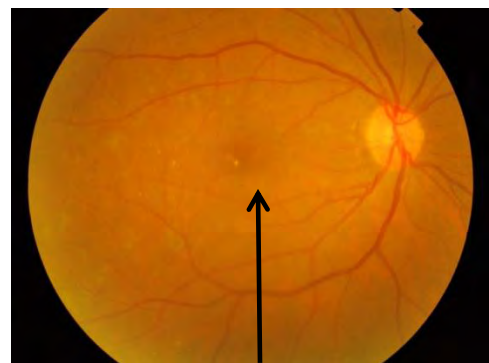
Hard exudates

01-05-2009 Vn:-6/9 N6



Hard exudates Cleared

01-05-2009 Vn:- 6/9 N6



Hard exudates Cleared

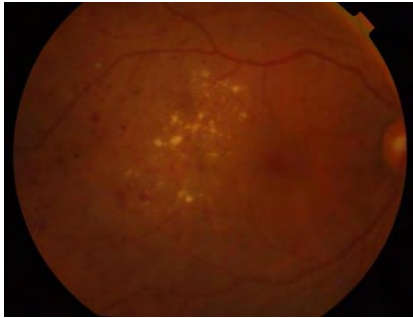


## 5. Resolution of diabetic macular edema with laser

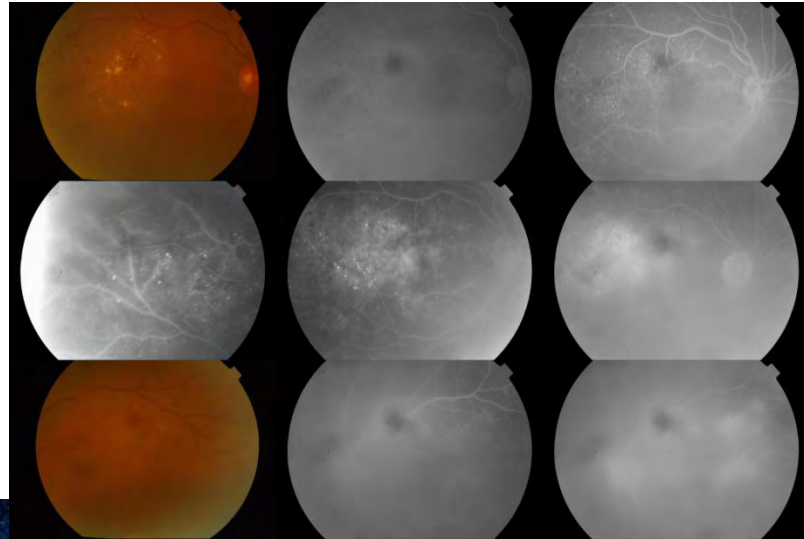
- This 62 year old female had diabetic maculopathy in the right eye.
- She underwent 2 sittings of focal laser for the same, on 04-07-2013 and 28-10-2013.
- The exudates resolved with laser alone.

**Ref No:- 08-00189**

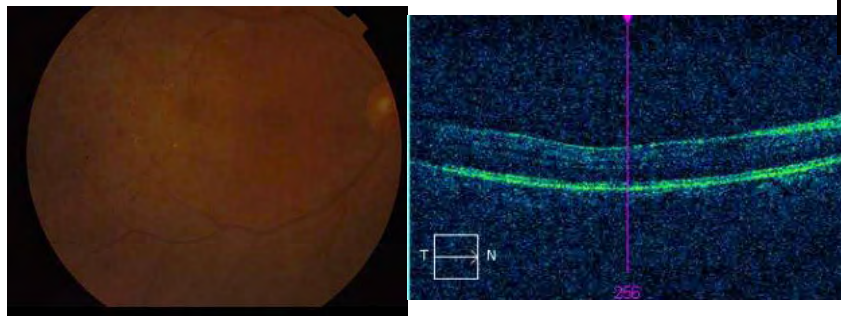
**27-06-2013 Pre focal laser 6/12p**



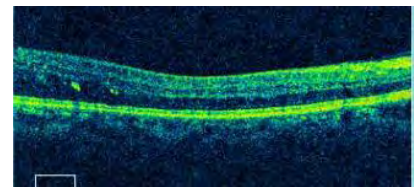
**26-04-2013 Vn: 6/36p N18**



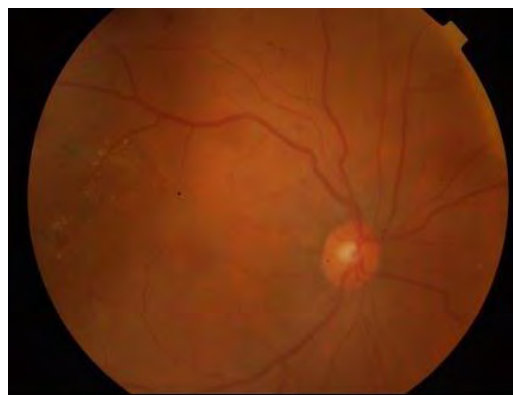**06-01-2014 Post focal laser 6/18p N10p**



**26-04-2013**



**06-06-2014 Last 6/24p N12**

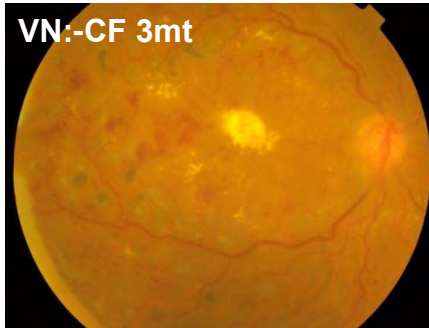


## 6. Improvement in macular edema with metabolic control, laser and steroid injection

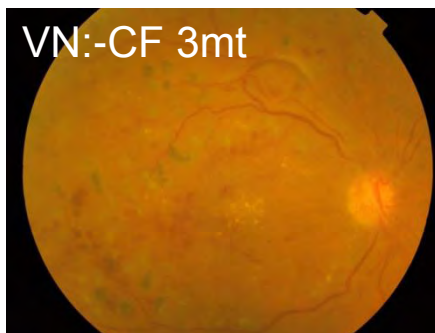
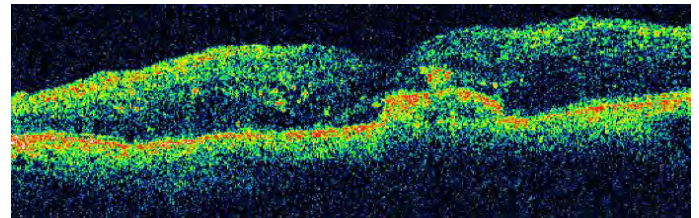
- Investigations showed mild anemia, increased lipids, and urine proteins +.
- She was advised to control her lipids and improve anemia.
- On 8-9-08 she underwent focal and PRP laser and received IVTA injection in right eye.
- Post injection and laser her vision improved to 6/12, N10 and edema significantly reduced

**Ref No : 31467**

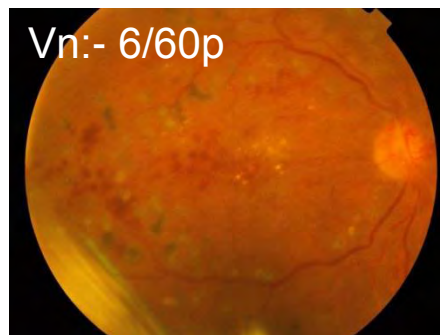
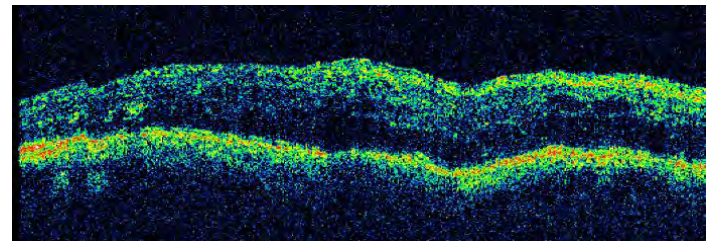
systemic control



23-04-08

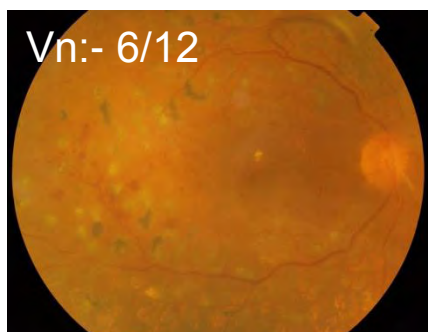
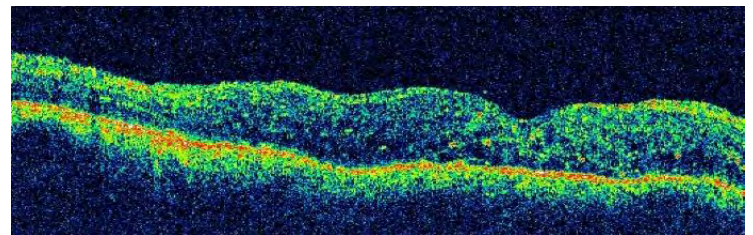


06-09-08



IVTA given on 08-09-08

15-09-08  
Post IVTA



02-03-2009

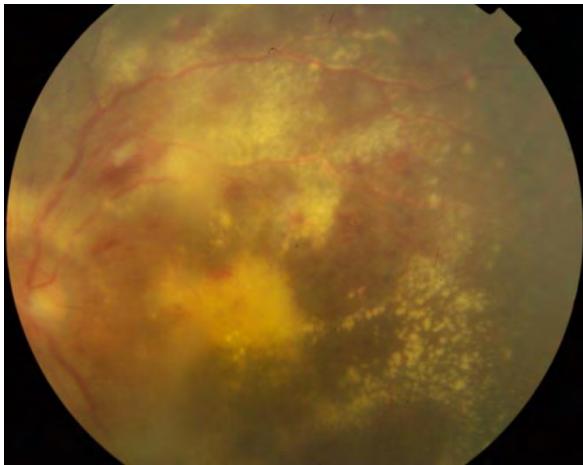


## **7. Resolution of macular edema with laser and metabolic control**

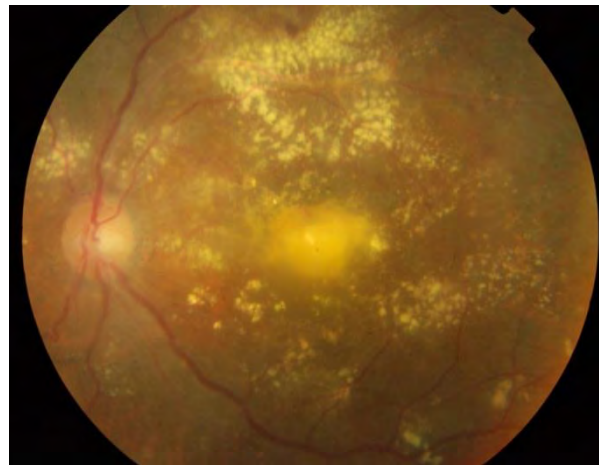
- This 65 year old male came with reduced vision in left eye.
- Vision was CF 3 mts, fundus showed lot of exudates at macula.
- Investigations showed diabetes and lipids both were raised.
- With metabolic control, the exudates reduced.

### **Ref No 30791**

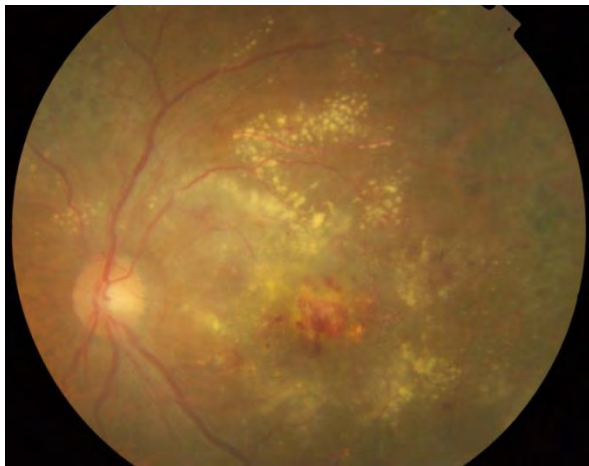
29-01-2008 CF 1ft



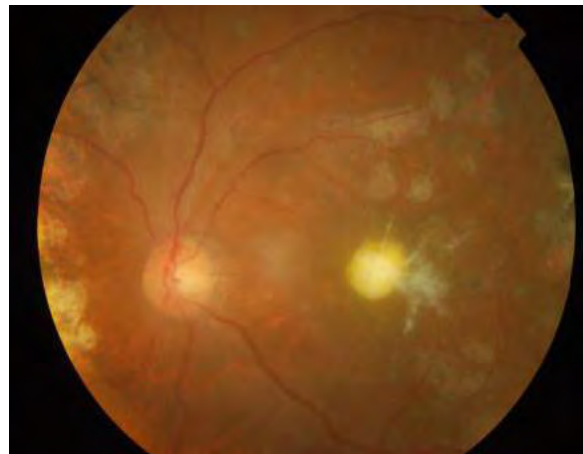01-08-2008 6/60p



24-12-2008 VN:-CF@ 1mt



10-05-2012 VN:-CF@ 1mt <N36

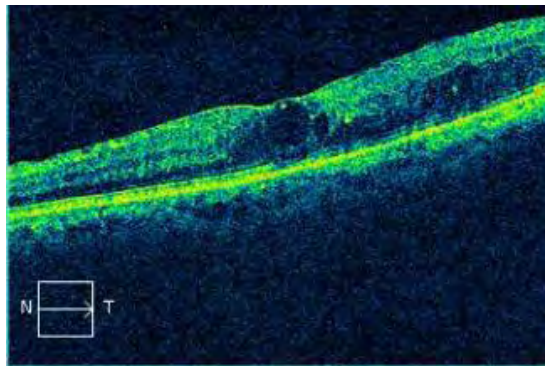
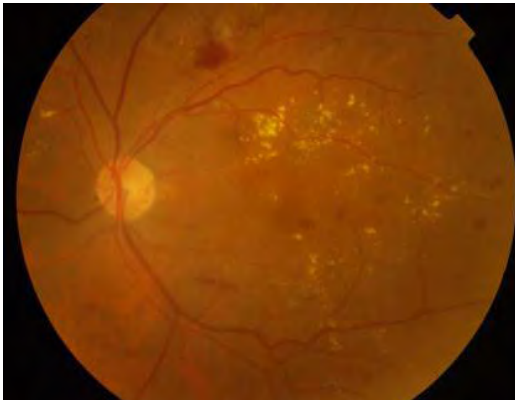


## **8. Resolution of macular edema with laser and metabolic control**

- This 77 year old male presented with vision of 6/18, N10 in left eye with diabetic maculopathy.
- He underwent one session of focal laser to microaneurysms,
- following which edema resolved and vision improved to 6/12, N10

**Ref No:-13-01273**

**Pre Laser 09-07-2013 Vn:- 6/18**



**Post Laser 21-07-2014 Vn:- 6/12**

