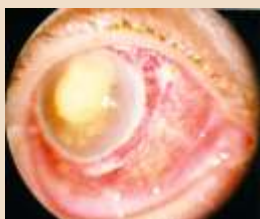
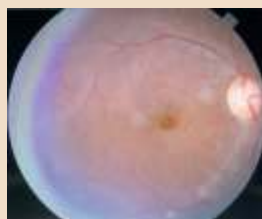


FUNDUS PHOTOGRAPHS



BEFORE SURGERY



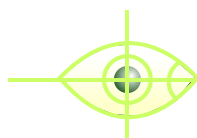
AFTER SURGERY

Treatment of Endophthalmitis

Once the diagnosis is made, prompt treatment is mandatory for better visual outcome. Treatment depends on the underlying cause of endophthalmitis.

If visual acuity is Hand Movement or better, intravitreal injection of antibiotics is given along with frequent instillation of drops. Patient may need to be hospitalized for adequate care. If vision is only Perception of Light, then the surgery called vitrectomy is performed to remove infecting organisms. Intravitreal injection is also injected along with frequent instillation of drops.

If there is associated foreign body or trauma then specific surgery is also required.



Drushti

Eye & Retina Centre
& Rajvi Nursing Home

ISO 9001 : 2000 Certified

Dr. Vatsal S. Parikh M.S., D.O.M.S., F.C.P.S.

FELLOW SANKARA NETHRALAYA, (CHENNAI)

210-211, Radhe Vallabh C.H.S. (Formerly Modi Chambers),
2nd Floor, French Bridge Corner, Opera House, Mumbai - 400 004.

Tel. : +91-22-2388 0505, 2380 4086, 2386 4191

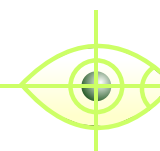
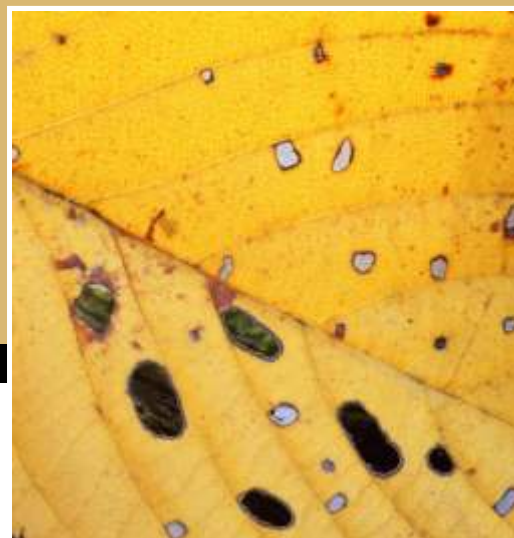
Resi. : 2367 7111, 2361 2996 • Fax : 2388 7738

Email : rajvi@vsnl.com • Website : www.drushti.com

Timing : Mon. to Fri. 3.30 to 8.30 p.m. Sat. 9 a.m. to 1 p.m.

Donate Eyes, Restore Sight

ENDOPHTHALMITIS



Drushti

Eye & Retina Centre
& Rajvi Nursing Home



Putting 'EYE' before 'I'

Specialist in Diseases of Vitreous & Retina
Lasers & Ultra Sonography & Microsurgery of Eye

This is the most dreaded complication after any eye surgery. If left untreated it may lead to painful, loss of vision. Though rare, it does occur and needs treatment on war footing. Any person complaining of sudden pain and loss of vision within 6 weeks of any eye surgery should rush to the operating surgeon, because he may be having intraocular infection.

What is Endophthalmitis?

It is an inflammation of internal coats of the eye including intraocular cavities (which contains gel like structure called vitreous), usually caused by an infection and rarely by non infectious agents like retained lens material or toxic agents. If all the 3 coats of the eye are involved than the condition is known as Panophthalmitis.

What are the types of Endophthalmitis?

If broadly classified, it is of 2 main types:

Endogenous Endophthalmitis: It is due to direct spread through the blood. Due to breakdown of blood aqueous barrier, organisms reach directly from blood to eye. This type is more common among IV drug abusers, immunosuppressed patients like those suffering from AIDS or malignancies, in patients undergoing invasive procedures such as prosthetic heart valve surgery, hemodialysis, bladder catheterization, gastrointestinal endoscopy, chemotherapy, dental procedures etc. Systemic diseases like diabetes mellitus, SLE, hepatitis, chronic renal failure, bone marrow transplantation etc. also predisposes to this condition.

In 50% of cases, endogenous endophthalmitis is caused by fungal infections due to candida species or aspergillosis. Bacterial infections are mainly due to gram positive organisms like *S. aureus*, *S. pneumoniae*, *S. Viridians* or gram negative organisms like *E. coli*, *Klebsiella*, *H. Influenza* and *Pseudomonas*.

Exogenous Endophthalmitis:

It is due to inoculation of infectious organisms from outside. Two most common types are:

a) **Post-operative:** It is seen mainly after intraocular surgeries like cataract, glaucoma or vitreo-retinal surgeries. Organisms usually reside in the eyelid margin or conjunctiva or are introduced into the eye if proper antiseptic precautions are not taken. Mainly gram positive organisms are responsible for this.

b) **Post-Traumatic:** It is seen mainly after penetrating injury with stick, vegetable matter, and metallic foreign bodies. Organisms are introduced into the eye during the injury.

What are the Symptoms?

Generally, patient complains of sudden loss of vision, pain, redness, swelling of the eye, headache, and photophobia. However severity of symptoms may depend on the causative organism. E.g.: Fungal infection usually has slow, indolent course with less inflammation compared to bacterial infections.

How to diagnose Endophthalmitis?

Proper examination by an eye specialist is must to diagnose and treat it adequately. Slit lamp and Indirect Ophthalmoscopic examination helps in the diagnosis. On examination, patient may have lid or periocular edema, redness of eyeball, hypopyon, vitritis, absent red reflex, papillitis proptosis, chronic uveitis, vitreal mass or debris etc. Some special tests help in pin pointing the causative organism, which helps in directing the treatment. Gramstain, blood culture, urine culture, vitreous or aqueous sample (from the eye), routine blood and urine test, chest x-ray, B-Scan of eye may be done if fundus is not well visualized.